

بِسْمِ اللَّهِ الرَّحْمَنِ الرَّحِيمِ



Shendi University



Faculty of Graduate Studies and Scientific Researches

**Assessment of nurse's knowledge and role
regarding medical imaging studies in Elmek
Nimer university hospital.**

*A thesis submitted in partial fulfillment for the requirement of
master degree in medical-surgical nursing*

By:

Nariman Foud Abdelwahab


Supervisor:

Dr. Mohammed Jebreldar Abuanja Nimer

B.sc.M.sc. PhD community health nursing

December 2014

الآية



بِسْمِ اللَّهِ الرَّحْمَنِ الرَّحِيمِ

Dedication

To

*My life for her patience, understanding, and
encouragement.*

To

*Who help me to reach this stage
I would like to dedicate this Work*

My baerant

To

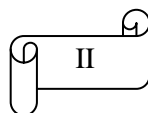
My sister for their supporting me.

To

My friends for their valuable advice.

To

My supervisor Dr. Mohamed jeber eldar



Acknowledgement

First, I would like to thank Allah who blessed me with the courage for preparation and completion of this study.

Words cannot express the special appreciation and deepest. I feel towards my supervisor

Dr. Mohamed jeber elder for this continuous significant encouragement and support throughout this thesis.

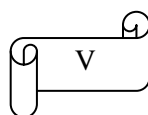
Thanks for all my friends whom helped me.

Thanks to everybody share me in preparation of this research and my teachers.

List of contents

<i>No</i>	<i>Subject</i>	<i>Page no</i>
1	الآية	I
2	الإهداء	II
3	الشكر والعرفان	III
4	List of content	IV – VI
5	List of tables	VII-VIII
6	List of figures	IX
7	List of abbreviations	X
8	ملخص البحث	X
9	Abstract	XI-XII
<i>Chapter one</i>		
10	Background	1-2
11	Justification	3
12	Objective	4
<i>Chapter two : Literature Review</i>		
13	1.1Introduction	5
	2.1Main article: Medical radiography	6
	2.3Fluoroscopy	8
	2.4Contrast-mediated studies	9
	2.5Radiation exposure risks	10
	2.5 Skull films	11
	2.5.1. Interfering factors	11
	2.5..2 Indications for skull films	11
	2.5.3Contraindication	12
	2.5.4Nursing care before the procedure	12
	2.5.5Prepare for the procedure	12
	2.5.6Nursing care after the procedure	13
	2.6 Chest films	13
	2.6.1.Interfering factors	14
	2.6.2Indications for chest films	14
	2.6.3 Contraindications	15
	2.6.4Nursing care before the procedure	15

2.6.5 The procedure	15
2.7 Abdominal films	15
2.7.2 indications for abdominal films	16
2.7.3 Contraindications	16
2.7.4 Nursing care before the procedure	16
2.7.5 The procedure	16
2.7.6 Nursing care after procedure	17
2.8 Tomography	17
2.8.1 chest tomography	18
2.8.2 interfering factors	18
2.8.3 indications for chest tomography	18
2.8.5 Nursing care before the procedure	18
2.8.7 Nursing care after the procedure	19
2.9 contrast-mediated studies	19
2.10 barium swallow	19
2.10.1 interfering factors	20
2.10.3 contraindications	21
2.10.4 nursing care before the procedure	21
2.10.5 Prepare for the procedure	22
2.10.7 Nursing care after the procedure :	23
3.1 Radiologic Angiography Studies	23
3.1.1 Cardiac angiography :	25
3.1.3 Indications for cardiac angiography	26
3.1.4 Contraindications	27
3.1.5 Nursing care before the procedure	27
3.1.7 Prepare for the procedure	28
3.1.8 Nursing care after the procedure	31
3.2 Ultrasound Studies	32
3.2.1 Ultrasound risks	34
3.2.2 Ultrasound procedures	34
3.2.3 Abdominal ultrasonography	35
3.2.3.1 Nursing Interventions	35
3.2.4 Abdominal/aortic ultrasonography	36
3.2.4.1 Interfering factors	36
3.2.4.2 Indications for abdominal/aortic ultrasonography	36
3.2.4.3 Nursing care before the procedure	37
3.2.4.4 The procedure	37
3.2.5 Bladder ultrasonography	38



	3.2.5.1 interfering factors	38
	3.2.5.2 indications for bladder ultrasonography	38
	3.2.5.3 Nursing care before the procedure	39
	3.2.5.4the procedure	39
	3.2.5.5Nursing care after the procedure	39
	3.3. echocardiography	39
	3.3.1 interfering factors	40
	3.3.2 indications for echocardiography	41
	3.3.3 Nursing care before the procedure	42
	3.3.4 Prepare for the procedure:	42
	3.3.6 Nursing care after the procedure	43
	3.3.7 Nursing interventions	43
	4.1 Magnetic resonance imaging	44
	4.2 Nursing care before the procedure	44
<i>Chapter three : Methodology and Material</i>		
14	Study design	46
	Study area	46
	Study population	46
	Sample size and selection	46
	Research tools	46
	Study technique	46
	Data entry and statistical analysis	47
<i>Chapter four</i>		
15	Results	48 - 60
<i>Chapter five</i>		
16	Discussion	61 - 62
17	Conclusion	63
18	Recommendation	64
<i>Chapter six</i>		
19	Reference	65-66
20	Appendix	67

List of tables

<i>Table number</i>	<i>List of table</i>	<i>Pages</i>
<i>Questionnaire analysis</i>		
Table 1	Distribution of nurses according to their socio-demographical data(age, gender, level of education and experience)	48
Table 2	Distribution of nurses according to their knowledge regard medical imaging definition	49
Table 3	Distribution of nurses according to their knowledge regard medical imaging techniques	49
Table 4	Distribution of nurses according to their knowledge regard general nursing care of patient for medical imaging	50
Table 5	Distribution of nurses according to their knowledge regard consent request	50
Table 6	Distribution of nurses according to their knowledge regard types of radiologic angiography	51
Table 7	Distribution of nurses according to their knowledge regards X .Ray using	52
Table 8	Distribution of nurses according to their knowledge regards pre - nursing care of x ray film and C.T scan	52
Table 9	Distribution of nurses according to their knowledge regards the route and the hazard of Contrast media for x-ray	63
Table 10	Distribution of nurses according to their knowledge	54

	regards the patient fasting for ultra sound test	
Table 11	Distribution of nurses according to their knowledge regards the advantage of ultrasound	55
Table 12	Distribution of nurses according to their knowledge regards the purpose of Fluoroscopy	55
Table 13	Distribution of nurses according to their knowledge regards the interfering factor with barium swallow and advice after barium swallowing procedure	56
Table 14	Distribution of nurses according to their knowledge regards indications for echocardiography and nursing care for patient in echo	57
Table 15	Distribution of nurses according to their knowledge regards interfering factor for MRI	57
Table 16	The relation between the years of experience and general nursing care for patient for medical imaging	58
Table 17	The relation between the years of experience and the hazard of radiation with contrast media	59
Table 18	The relation between the level of education and nursing care for patient undergoing medical imaging depend on	60

List of figures

<i>Number of figure</i>	<i>Content of the figure</i>	<i>Pages</i>
<i>Figure 1</i>	Distribution of nurses according to their knowledge regard nursing care for patient undergoing medical imaging depend on:	51
<i>Figure 2</i>	Distribution of nurses according to their knowledge regards Ct scans usage	53
<i>Figure 3</i>	Distribution of nurses according to their knowledge regards interfering factors for abdomen ultrasound	54

ملخص البحث

هذه الدراسة الوصفية المقطعية أجريت في مستشفى المك نمر الجامعي في الفترة (يوليو - ديسمبر 2014م) بهدف تقييم معرفة تقني التمريض بخصوص معرفتهم ودورهم في إجراء التصوير الطبي. شملت الدراسة (80) من تقني تمريض العاملين بمختلف الورديات وتم اختيارهم بالطريقة العشوائية البسيطة. تم جمع البيانات عن طريق (الاستبيان)، البيانات المجمعة عولجت وحُللت بواسطة برنامج الحزم الإحصائية للعلوم الاجتماعية (SPSS)، وعرضت في جداول وأشكال.

وجد في هذه الدراسة، أن أقل من نصف الممرضين (45%) عرفوا التصوير الطبي علي انه إجراء تشخيصي وعلاجي. في حين أن أكثر من ثلثي الممرضات (73.7%) ذكروا ان الرعاية التمريضية للمريض الذي يخضع للتصوير الطبي تعتمد على نوع التصوير الطبي وهذا يعني ان تقني التمريض لديهم مستوى تعليمي جيد (بكالوريوس). وذكرت الدراسة أن ثلثي مجتمع الدراسة (66.2%) لديهم معرفة ضعيفة عن الغرض من التنظير الطبي، لأن معظم تقني التمريض ليس لديهم أي تدريب عن التنظير.

أوضحت هذه الدراسة أكثر من خمسي (45%) من الممرضين وازحو أن الأشعة المقطعية تستخدم في الأنسجة اللينة والأورام. هذا يوضح المعرفة الجيدة للممرضين والممرضات حول هذا الموضوع. ورغم أن النتيجة تظهر ضعف المعرفة عن طريقة ومخاطر التصوير الإشعاعي للقلب. لأن هذا التصوير يتم عند إجراء قسطرة في القلب ومعظم الممرضين يعملون في أماكن ليس لها علاقة حول هذا الموضوع. هناك كانت علاقة ذات دلالة إحصائية بين مستوى التعليم والرعاية التمريضية للمرضي يخضعون التصوير الطبي (قيمة ب 0.03).

أكثر من نصف مجتمع الدراسة (52.5%) لديه معرفة جيدة عن دواعي تصوير القلب والرنين المغناطيسي، والرعاية التمريضية للمريض. على الرغم من أن التصوير بالرنين المغناطيسي لا تتوفر في المستشفى.

لضمان التطبيق الأمثل والالتزام بهذه الدراسة، توصي الدراسة بأن يكون هنالك تطوير لبرامج التعليم المستمر لتقني التمريض بخصوص التصوير الطبي بالمستشفى.

Abstract

This descriptive s-cross sectional study was carried out in Elmek Nimer university hospital in a period of (July – December 2014). The aim of this study is to assess nurse's knowledge and role regarding medical imaging studies. The study include all nurses working in three shift and they are about 80 nurse. Nurses are selected by simple random sampling. The data was collected by structured standard questionnaire and the data were treated and analyzed by (SPSS) and presented in table and figures.

The study shows that less than half of nurses define medical imaging as diagnostic and therapeutic procedure (45 %). While more than tow third (73.7%) of nurses mention nursing care for patient undergoing medical imaging depend on type of medical imaging This mean most of nurses in hospital good educated (baccloria). The study mentioned that two third (66.2 %) have a poor knowledge about purpose of Fluoroscopy ,because the most of nurse have no endoscopy training.

In this study more than two fifth (45 %) of nurses mentioned C.T scan used for soft tissue and lesion .That clarify of good knowledge for nurses about it. While the result show poor knowledge about rout and hazard of contrast media because this procedure perform in cardiac catheter and nurse in other department not wear about it .There were insignificant relation between the level of education and nursing care for patient undergoing medical imaging(P value = 0.03.). more than half (52.5) of nurses has a good knowledge about indications for echocardiography, and nursing care for patient in echo, respectively. Because barium swallow study perform irregular procedure pattern . although MRI are not available in hospital in spite of good knowledge about echo.

To ensure perfect application and compliance with this study, the study recommends that establish continuous local education and training program for nurses regarding medical imaging in Elmek Nimir university hospital.

Background

Radiation is used daily in hospitals and clinics to perform diagnostic imaging procedures. For the purposes of this fact sheet, the word radiation refers to ionizing radiation. The most commonly mentioned forms of ionizing radiation are x rays and gamma rays. Procedures that use radiation are necessary for accurate diagnosis of disease and injury. They provide important information about your health to your doctor and help ensure that you receive appropriate care. Physicians and technologists performing these procedures are trained to use the minimum amount of radiation necessary for the procedure. Benefits from the medical procedure greatly outweigh any potential small risk of harm from the amount of radiation used (**National Radiation Laboratory, 2010**).

In x-ray procedures, x rays pass through the body to form pictures on film or on a computer or television monitor, which are viewed by a radiologist. If you have an x-ray test, it will be performed with a standard x-ray machine or with a more sophisticated x-ray machine called a CT or CAT scan machine. In nuclear medicine procedures, a very small amount of radioactive material is inhaled, injected, or swallowed by the patient. If you have a nuclear medicine exam, a special camera will be used to detect energy given off by the radioactive material in your body and form a picture of your organs and their function on a computer monitor. A nuclear medicine physician views these pictures. The radioactive material typically disappears from your body within a few hours or days.

MRI and ultrasound procedures do not use ionizing radiation. If you have either of these types of studies, you are not exposed to radiation .Your doctor will order an x-ray test for you when it is needed for accurate diagnosis of your condition.(**Cynthia C. etal,2008**).

Benefits from the medical procedure greatly outweigh any potential small risk of harm from the amount of radiation used. There is no conclusive evidence of radiation causing harm at the levels patients receive from diagnostic x-ray exams. Although high doses of radiation are linked to an increased risk of

cancer, the effects of the low doses of radiation used in diagnostic imaging are not known. No one is certain if any real risks are involved. Many diagnostic exposures are similar to exposure that we receive from natural background radiation found all around us. You will note that a few of the diagnostic exposures are much higher than background or that multiple exposures will give an accumulated exposure higher than background. Nevertheless, benefits of diagnostic medical exams are vital to good patient care (http://en.wikipedia.org/wiki/Medical_imaging).

Justification

Medical imaging has previously been identified as one of the fastest growing of all health care sectors. More recently, though, data from a variety of sources reveal a dramatic and sustained slowing- and now a decline – in both utilization and spending. The outcomes and cost implications on individual patients and the health care delivery system at large are not yet known. **(Neiman, 2012).**

In fact the patients in Elmek Nimer whose undergoing medical imaging are not preparing well by most of the nurses which need more and comprehensive nursing care. This study will assess nurses knowledge about medical imaging which could affect the diagnose perhaps the treatment of the patient.

Objectives

❖ **General objective:**

Assessment of nurse's knowledge and practice regarding medical imaging studies in Elmek Nimer university hospital.

❖ **General objective:**

- To assess nurses knowledge about medical imaging.
- To identify nurses knowledge about role of nurse for patient undergoing medical imaging.
- To identify indication and complication of radiological examination.
- To evaluate the nurses knowledge about nursing care of post radiological examination.

2.1 Introduction:

Radiologic imaging is the technique, process and art of creating visual representations of the interior of a body for clinical analysis and medical imaging is the technique, process and art of creating visual representations of the interior of a body for clinical analysis and treat disease. Medical imaging also establishes a database of normal anatomy and physiology to make it possible to identify abnormalities(Sandra M.Nettina, 2001)

Although imaging of removed organs and tissues can be performed for medical reasons, such procedures are usually considered part of pathology instead of medical imaging As a discipline and in its widest sense, it is part of biological imaging and incorporates radiology which uses the imaging technologies of X-ray radiography, magnetic resonance imaging, medical ultrasonography or ultrasound, endoscopy, elastography, tactile imaging, thermography, medical photography and nuclear medicine functional imaging techniques as positron emission tomography (Brunner-suddarth, 2010).

Measurement and recording techniques which are not primarily designed to produce images, such as electroencephalography (EEG), magnetoencephalography (MEG), electrocardiography (ECG), and others represent other technologies which produce data susceptible to representation as a parameter graphs. time or maps which contain information about the measurement locations. In a limited comparison these technologies can be considered as forms of medical imaging in another discipline(http://en.wikipedia.org/wiki/Medical_imaging.)

Up until 2010, 5 billion medical imaging studies had been conducted worldwide. Radiation exposure from medical imaging in 2006 made up about 50% of total ionizing radiation exposure in the United States.

In the clinical context, "invisible light" medical imaging is generally equated to radiology or "clinical imaging" and the medical practitioner responsible for interpreting (and sometimes acquiring) the images is a radiologist. "Visible light" medical imaging involves digital video or still

pictures that can be seen without special equipment. Dermatology and wound care are two modalities that use visible light imagery. Diagnostic radiography designates the technical aspects of medical imaging and in particular the acquisition of medical images. The radiographer or radiologic technologist is usually responsible for acquiring medical images of diagnostic quality, although some radiological interventions are performed by radiologists. While radiology is an evaluation of anatomy, nuclear medicine provides functional assessment (http://en.wikipedia.org/wiki/Medical_imaging)

Medical imaging is often perceived to designate the set of techniques that noninvasively produce images of the internal aspect of the body. In this restricted sense, medical imaging can be seen as the solution of mathematical inverse. This means that cause (the properties of living tissue) is inferred from effect (the observed signal). In the case of medical ultrasonography, the probe consists of ultrasonic pressure waves and echoes that go inside the tissue to show the internal structure. In the case of projectional radiography, the probe uses X-ray radiation, which is absorbed at different rates by different tissue types such as bone, muscle and fat.

The term noninvasive is used to denote a procedure where no instrument is introduced into a patient's body which is the case for most imaging techniques used Dies. (http://en.wikipedia.org/wiki/Medical_imaging)

2.1 Medical radiography

Two forms of radiographic images are in use in medical imaging; projection radiography and fluoroscopy, with the latter being useful for catheter guidance. These two dimension techniques are still in wide use despite the advance of three dimension tomography due to the low cost, high resolution, and depending on application, lower radiation dosages. This imaging modality utilizes a wide beam of x rays for image acquisition and is the first imaging technique available in modern medicine.

(http://en.wikipedia.org/wiki/Medical_imaging).

2.1 X-ray:

Are used to evaluate the bones and soft tissues of the body. In photographic film, x-rays cause silver to precipitate. This precipitation causes the film to turn black when it is developed. Objects placed between the beam of x-rays and the photographic films absorb some of the x-rays and cause a shadow to be cast upon the film. The amount of x-rays absorbed varies with the thickness and composition of the object. Metal, for example, absorbs all of the x-rays and no silver is precipitated; when the film is developed, the object appears solid white. In contrast, soft tissues absorb only part of the x-rays and cause a grayish shadow to be cast on the film. The usefulness of diagnostic radiography is based on the differences in the absorption of rays by various substances or objects. Because x-rays precipitate silver in photographic film slowly, clients may potentially be exposed to unduly long studies and excessive radiation. To avoid these problems, special film cassettes are used.

These cassettes contain a fluorescent screen that is activated by the x-rays and emits light rays that augment the effects of x-rays on the photographic film. (http://en.wikipedia.org/wiki/Medical_imaging)

Xeroradiography is an x-ray imaging technique that uses a photoelectric process rather than the photochemical process of conventional x-rays; this process reduces the amount of radiation exposure to the client. The images are printed on paper. For many body parts, such as bones and air-filled soft structures, differences in composition and density produce natural contrasts that are sufficient for “plain” films of diagnostic quality. Solid organs and hollow structures that do not normally contain air, however, require either special filming techniques such as tomography or use of radiopaque contrast media such as barium sulfate or iodinated dyes for accurate imaging.

Radiographic procedures can be either invasive or noninvasive, and client preparation varies accordingly. In the case of noninvasive procedures such as plain-film x-rays, tomography, and those using barium sulfate as a contrast medium, the client should be told what to expect, but a signed consent form is

not required. The only exception to this is mammography, which uses xeroradiography to create its images. A signed consent form is required for invasive procedures that use iodinated dyes administered intravenously (IV) or directly into an organ or area to be examined. The procedures are usually performed in the radiology department or a special room with x-ray equipment, but some can be performed at the bedside, in the physicians' office, or at an imaging agency. (<http://pubs.rsc.org/en/content/articlepdf/2013/AN/C3AN00698K>)

2.3 Fluoroscopy

Fluoroscopy is an imaging technique in which x-rays are passed through the client to a fluorescent viewing screen coated with calcium tungstate. The viewer is able to observe movement in the area being filmed while the study is in progress, making fluoroscopy particularly useful in evaluating movement of the diaphragm, heart, and digestive system (esophagus, stomach, small bowel, colon). It is also used in catheter guidance for placement during angiography, needle insertion for biopsy or removal of fluid from a body cavity, and nasogastric (NG) tube insertion for precise placement in the stomach or small bowel. Fluoroscopy can be used with single films (spot films) or with videotape if a record of movement is desired. Fluoroscopy is also often used in combination with other radiologic procedures and techniques, such as plain films or cineradiography, and it is frequently augmented by the addition of a contrast medium such as barium sulfate.

The viewer faces the screen during fluoroscopy and thus can be exposed to x-rays. For this reason, the viewer must wear special lead-shielded glasses, gloves, and aprons for protection. Fluoroscopy delivers much larger doses of radiation than conventional x-rays. Such studies can be performed by a qualified radiologist, urologist, or x-ray technician. All invasive radiologic procedures are performed under sterile conditions using standard.

Preparation:

- The client should remove all upper body clothing, jewelry, and metal items.
- Just before beginning the procedure, take a “time out” to verify the correct client, procedure, and site.

Procedure:

- The client stands with the chest between the x-ray tube and the fluoroscopic screen
- Remove electrocardiographic monitoring leads and patches containing metal snaps and safety pins. Move invasive lines out of the fluoroscopic field if possible
- Proceed with fluoroscopy. The client turns in different projections for the procedure.

Factors That Affect Results:

Metallic objects may interfere with the quality of films obtained by fluoroscopy. (Cynthia C. etal,2008)

2.4 Contrast-mediated studies

Soft tissues produce poor images on x-ray, and contrast media are added to enhance the viewing of structural details. A contrast medium can be administered orally, rectally, IV, intrathecally, or by insufflations. When contrast media are injected to visualize blood vessels and lymphatic, the studies are referred to as angiography.

The most commonly used contrast media are barium sulfate, organic iodides, and iodized oils. These substances are radiopaque and block the passage of x-rays. Gases such as oxygen, carbon dioxide, helium, nitrogen, and air have been used to render body spaces radiolucent because the spaces partially block the passage of x-rays. Many of the studies in which gases are used have now been replaced by safer, noninvasive CT and other imaging techniques. In addition to the radiation hazards inherent in all x-ray studies, contrast-mediated procedures pose the additional risk of severe allergic reaction to the iodinated

contrast medium, including vomiting, laryngospasm, anaphylactic shock, and cardiac arrest .Emergency equipment should be at hand so that resuscitative measures can be initiated immediately.

Barium sulfate is a chalky emulsion that is flavored and aerated to the consistency of a milk shake. Oral ingestion of this medium can lead to nausea and vomiting as well as to prolonged retention of the barium within the intestinal tract, leading to constipation and impaction. The color of the feces will be white or much lighter than usual until the barium is eliminated from the tract(**Bonita Morrow and Cavanaugh, 2003**)

2.5 Radiation exposure risks

All radiation studies carry risks of exposure to radiation. Radiation can have adverse effects on both gonadal and somatic cells. The cells of the developing embryo are especially sensitive to radiation.Children are at higher risk than adults, so this diagnostic method should be used only when absolute necessary. Possible adverse effects of radiation include genetic mutations, cancer, and congenital anomalies.

x-ray studies should not be performed more often than necessary for diagnosis. Clients should be adequately prepared so that the need for repeat films and studies is reduced. Newer x-ray equipment should be used because they expose clients and personnel to less radiation than older equipment. Personnel and clients should be shielded from unnecessary exposure by lead aprons and gloves. Women who are pregnant should not be x-rayed, and women of childbearing age should be assessed for the date of the last menstrual period to reduce the possibility of having radiographic studies performed during pregnancy. If undiagnosed pregnancy is a risk or if a pregnancy is not confirmed, the study is generally not performed unless it is an extreme necessity.

2.5 Skull films

Skull films involve radiographic examination of the cranial vault and facial bones. A variety of abnormalities can be identified on skull films, such as fractures, tumors, and changes in bone structure or size. Several views are taken, depending on the signs and symptoms and the suspected pathology. In cases involving fractures of the cervical vertebra positioning to obtain varied views is limited.

2.5.1. Interfering factors

Improper positioning to achieve the desired views Limitations in positioning from known or suspected fractures of the cervical vertebrae. Metal objects such as dentures, hearing aids, and eyeglasses within the x-ray field

2.5.2 Indications for skull films

- Known or suspected trauma to the face or cranium to reveal a fracture
- Suspected increased intracranial pressure revealed by abnormal markings on the inside of the cranial vault
- Suspected pituitary tumor revealed by increased size and erosion of the sella turcica
- Suspected metastatic tumor involving the small bones or brain tissue revealed by a shift of intracranial contents
- Suspected acromegaly revealed by an enlarged mandible
- Suspected tumor or inflammation involving the paranasal sinuses
- Suspected Paget's disease revealed by a thickening of the skull bones
- Suspected vascular abnormalities such as chronic subdural hematoma revealed by calcifications in brain tissue
- Suspected perinatal injury or congenital defect involving the skull
- Evaluation of thinning of bones, separation of suture lines, widened fontanelles, and an enlarged cranium in the diagnosis of hydrocephalus in infants

Evaluation of premature closing of the cranial sutures in the diagnosis of craniostenosis in infants ((**Bonita Morrow and Cavanaugh, 2003**)

2.5.3 Contraindications

Pregnancy, unless benefits of performing the procedure greatly outweigh the risks to the fetus

2.5.4 Nursing care before the procedure

Explain to the client:

- The location for the procedure and the fact that a technician or radiologist will perform it
- That the procedure takes about 15 minutes
- That foods, fluids, and medications are not restricted before the procedure
- That no sedation or anesthetic is administered before the procedure
- That views may be taken with the client in various positions on the x-ray table or in an x-ray chair
- That the area to be examined will be immobilized or the client will be asked to remain still during the procedure
- That the procedure should not cause discomfort, except possibly from lying on the hard table.

(**Bonita Morrow and Cavanaugh, 2003**)

2.5.5 Prepare for the procedure:

- Obtain a history of known underlying medical conditions or trauma and (for women) date of last menstrual period to determine the possibility of pregnancy.
- Ensure that all dental prostheses, jewelry, eyeglasses, or other metal objects such as hair clips are removed.
- Provide a hospital gown, if needed.
- Perform baseline neurological check and vital signs for later comparison readings.
- Normal skull, facial, and jaw bones; normal brain tissue; normal suture lines and fontanel in infant

2.5.6 Nursing care after the procedure

- Perform neurological checks and vital signs and compare with baselines.
- Complications and precautions: Note and report suspected fracture or injury to the cervical spine or neck pain. Consider this limitation when positioning the neck during the x-ray procedure. (**Bonita Morrow . Cavanaugh 2003**)

2.6 Chest films

Chest x-rays (CXR) are among the most frequently performed radiologic studies and yield a great deal of information about the pulmonary and cardiac systems. The lung fields, the clavicle and ribs, the cardiac border, the mediastinum, the diaphragm, and the thoracic spine can all be studied using CXRs. (Penelope Ann Hilton, 2004)

Although generally performed in the radiology department, chest x-rays using portable equipment can be taken at the client's bedside in more acute or critical situations. Although only a single view is obtained, critical problems such as pneumonia, atelectasis, pneumothorax, pulmonary edema, and pleural effusion can be identified. In addition, portable chest x-ray equipment is often used to evaluate the placement of various tubes, such as central venous catheters.

Chest x-ray studies can include several views. In the posterior-anterior (PA) view the x-ray beam passes through the client from back to front. This is a preferred view because it results in less magnification of the heart than does the anterior-posterior. The farther away from the x-ray film an object is situated, such as the heart , the more magnified and less distinct will be its image., however, that portable chest x-rays are performed using the view. The lateral view is performed with the client's left side placed against the film and the arms positioned to avoid interference with the chest view. The rationale for this position is the same as for the that is, the heart lies toward the left side of the chest and is less magnified in the left lateral view

The radiology department performs diagnostic x-ray studies to aid healthcare providers in determining the exact location and nature of disorder .(**Caroline Bunker Rosdahl, Mary T. Kowalski, 2012.**)

2.6.1. Interfering factors

- Improper positioning, especially for views such as the oblique and lordotic films or for portable chest x-rays
- Inability of client to take and hold deep breaths during the filming
- Improper adjustment of the x-ray equipment to accommodate obese and thin clients, causing over exposure or underexposure and poor-quality films
- Metal objects such as closures on undergarments or hospital gown within x-ray field.

2.6.2 Indications for chest films

- Known or suspected pulmonary infectious disorders such as pneumonia, tuberculosis, or lung abscess
- Diagnosis of obstructive pulmonary lung diseases such as atelectasis, emphysema, or chronic bronchitis
- Diagnosis of interstitial lung diseases such as sarcoidosis, silicosis, or asbestosis
- Diagnosis of pneumothorax or fractures of the ribs or clavicles resulting from known or suspected chest trauma
- Known or suspected cardiovascular disorders such as congestive heart failure (CHF), pericarditis, or aortic aneurysm
- Monitoring of pulmonary or cardiac disease to evaluate the effectiveness of therapy
- Suspected diaphragmatic hernia
- Suspected neoplasm (benign or malignant) involving the mediastinum, lungs, or chest wall
- Suspected pleural effusion or other abnormalities involving the pleurae or fluid accumulation in the lungs, as in pulmonary edema

- Diagnosis of cystic fibrosis in children
- Diagnosis of bronchopulmonary dysplasia, air leak syndrome, hyaline membrane disease, and meconium aspiration syndrome in infants
- Evaluation of the placement and positioning of endotracheal tubes, tracheostomy tubes, central venous catheters, Swan-Ganz catheters, chest tubes, NG feeding tubes, pacemaker wires, and intra-aortic balloon pumps (Bonita Morrow . Cavanaugh 2003)

2.6.3 Contraindications:

Pregnancy, unless benefits of performing the procedure greatly outweigh the risks to the fetus

2.6.4 Nursing care before the procedure:

Client teaching and physical preparation are the same as for any plain x-ray procedure .

2.6.5 The procedure:

- For Routine Films. The client is positioned in front of the x-ray machine and against the film holder.
- The client can be seated if unable to stand. For the PA view, the client stands or sits facing the film with the hands on the hips, neck extended, and shoulders forward and touching the film holder.
- The client is again requested to hold the breath while the x-ray is taken).

Bonita Morrow . Cavanaugh 2003)

2.7 Abdominal films:

A plain film of the kidneys, ureters, and bladder (KUB), also called a scout film or flat plate, consists of a single AP view of the abdomen. The abdominal film is commonly taken to assist in the diagnosis of urologic and gastrointestinal abnormalities.

2.7.1 interfering factors :

- Feces, barium or other radiopaque substances, gas, or ascites
- Extreme obesity, uterine and ovarian tumors or lesions
- Metal objects such as belts or girdles within the x-ray field

2.7.2 indications for abdominal films:

- Diagnosis of intestinal obstruction and acute abdominal pain of unknown etiology
- Evaluation of palpable abdominal mass
- Determination of size, shape, and position of kidneys to aid in the diagnosis of congenital anomalies and diseases such as absence of kidney or horseshoe kidney, hypoplasia, polycystic kidney disease, hydronephrosis, or atrophic kidney
- Determination of the size, shape, and position of liver and spleen in liver cirrhosis, splenomegaly, and tumors
- Suspected abnormal air, fluid, or objects in the abdomen Evaluation of size, shape, and location of renal calculi, revealed by visualization of opaque bodies
- Differentiation between the cause of urologic symptoms and gastrointestinal symptoms
- Initial component of a contrast-mediated study of the renal/urinary and gastrointestinal tract

2.7.3 Contraindications:

Pregnancy, unless benefits of performing the procedure greatly outweigh the risks to the fetus

2.7.4 Nursing care before the procedure:

Client teaching and physical preparation are the same as for any plain x-ray procedure

2.7.5 The procedure:

The client is placed on the x-ray table in the supine position with the arms extended over the head. A protective shield is placed over the testicular area of male clients. Usually a single AP film of the abdomen is taken, although a film with the client in a sitting or standing position may be performed, depending on the reason for the study.

During the Normal shape and size of kidneys, with the right kidney positioned slightly lower than the left; normal bladder, if visualized; no renal calculi, abdominal masses, abnormal accumulation of air or fluid, or foreign objects within the gastrointestinal tract filming, the client is requested to take a deep breath and hold it or exhale and not breathe. Visualization of the bladder depends on its density and whether it contains urine.

2.7.6 Nursing care after procedure :

- Care and assessment after the procedure are the same as for any plain x-ray procedure
- Monitor bowel sounds in clients who experience abdominal pain (**Bonita Morrow . Cavanaugh 2003**)

2.8 Tomography :

Tomography provides a two-dimensional image with clarity superior to that of plain films. It is especially valuable in visualizing air-filled structures such as the lungs and paranasal sinuses. The studies are contraindicated during pregnancy, unless the benefits of performing the procedure far outweigh the risks to the fetus. CT scans can also be used to guide some types of biopsies (the removal of a small amount of tissue for examination under a microscope to determine whether cancer is present) or to evaluate the effectiveness of cancer treatments, such as chemotherapy or radiation therapy. In addition, CT scans are often used for radiation therapy treatment planning. Areas that are commonly scanned include the head, neck, chest, abdomen, pelvis, or limbs.

Nursing Care:

During the CT scan, the patient must lie still on a moveable table. Noncontrast scans take approximately 10 minutes; contrast scans take between 20 and 30 minutes. Patients who are receiving dye should be warned that they may feel a sensation of warmth; Sedation may be required for patients who are agitated or disoriented. Patients who are in pain may require pain medication before the examination (**linda s. williams, paula d. hopper, 2003**).

2.8.1 Chest tomography:

Tomograms of the chest are valuable when the nature of lesions seen on routine chest x-rays must be determined or when routine films are negative but an abnormality is suspected. Tomography provides an image of the organ at different depths and angles and reveals parts not seen on plain radiographs .

Because the client is exposed to more radiation than with plain x-ray filming, tomography is used only when absolutely necessary. This procedure has been replaced by computed tomography of the **Bonita Morrow . Cavanaugh 2003)**

2.8.2 interfering factors:

- Inability of client to maintain required positioning and remain still during the study
Improper positioning of the client
- Metal objects such as jewelry or clothing fasteners within x-ray

2.8.3 indications for chest tomography:

- Further evaluation of abnormal pulmonary vasculature seen on chest x-ray
- Suspected lung tumor when plain chest films are negative
- Further evaluation of abnormal results of plain films of the chest that can include tuberculous cavitation, lung abscess, or calcifications
- Suspected tumor involving mediastinal structures, ribs, and spine

2.8.4 contraindications:

Pregnancy, unless benefits of performing the procedure greatly outweigh the risks to the fetus

2.8.5 nursing care before the procedure:

Client teaching and physical preparation .

2.8.6 the procedure;

The client is placed on the x-ray table in a supine position. Side-lying or prone positions can also be used for this study. The x-ray tube overhead is moved back and forth in a circular or a motion while the films are being taken. The client is requested to remain very still on the table but to breathe in a normal pattern. Normal lung fields, mediastinal structures, ribs, and thoracic spine

2.8.7 nursing care after the procedure:

Care and assessment after the procedure are the same as for any plain x-ray procedure(<http://www.cancer.net/navigating-cancer-care/diagnosing-cancer/tests-and-procedures>).

2.9 contrast-mediated studies:

Contrast-mediated studies are performed to visualize soft tissues that produce poor images on x-ray unless they are enhanced in some way. The most commonly used contrast media are barium sulfate and the organic iodides.

These substances are radiopaque and block the passage of the x-rays, resulting in the images on film. Signed informed consent forms are not obtained for procedures using a barium contrast medium but are required for those using iodinated contrast medium. Contrast media – Any internally administered substance that has a different opacity from soft tissue on radiography or computed tomography; includes barium, used to opacify parts of the gastrointestinal tract; water-soluble iodinated compounds, used to opacify blood vessels or the genitourinary tract; may refer to air occurring naturally or introduced into the body; also, paramagnetic substances used in magnetic resonance imaging (American Society of Radiologic Technologists.2014)

2.10 barium swallow:

A barium swallow (esophagography) involves the recording of radiographic images of the esophageal lumen while the client swallows barium solution. The test is performed using fluoroscopic and cineradiographic techniques and is recorded on film or videotape to evaluate both motion and anatomic structures. A barium swallow is often performed along with an upper gastrointestinal series. It is also performed as part of a cardiac series to visualize the size and shape of the heart and great vessels Barium sulfate solutions of both thick and thin consistencies are given.

A swallowed small cotton ball soaked in barium can be used to detect foreign bodies in the esophagus, because swallowing liquid barium occurs too rapidly for such objects to be visualized.58 Food items can also be coated with

barium to evaluate both chewing and swallowing. is not used if perforation or obstruction of the esophagus is suspected, because deposition of the barium in soft tissues can cause a serious inflammatory response. In such cases, a water-soluble solution of an iodinated contrast medium such as diatrizoate meglumine (Gastrografin) is used. Note, however, that some of these materials are irritating to the mucosa of the tracheobronchial tree and should not be used when tracheoesophageal fistula is suspected. The patient swallows barium under direct fluoroscopic examination. As the barium descends into the stomach, the position, patency, and caliber of the esophagus are visualized, enabling the examiner to detect or exclude any anatomic or functional derangement of that organ. (Suzanne C. O'Connell Smeltzer, Brenda G. Bare, 2014)

2.10.1 interfering factors:

- Inability of client to assume or remain in the proper position during the procedure
- Inability of client to swallow radiopaque substance or barium-coated items
- Foods and fluids ingested within 8 hours of the study
- Metal objects within the x-ray field

2.10.2 indications for barium swallow:

- Chronic difficult or painful swallowing (dysphagia), heartburn, or regurgitation of food.
- Suspected esophageal motility disorders such as achalasia, spasms of the esophageal muscles
- Diagnosis of esophageal reflux revealed by barium returning to the esophagus from the stomach
- Suspected strictures, polyps, Zenker's diverticulum, benign or malignant tumor of the esophagus
- Determination of whether sharp foreign object is caught in the esophagus after accidental swallowing

- Diagnosis of inflammatory or infectious process such as acute or chronic esophagitis Suspected congenital abnormality in infants such as tracheoesophageal fistula or atresia Suspected rupture of the esophagus .
- Suspected esophageal varices, although they are more likely to be detected by endoscopic procedures

2.10.3 contraindications:

- Pregnancy, unless benefits of performing the procedure greatly outweigh the risks to the fetus
- Allergy to iodine, if an iodinated contrast medium is used
- Suspected presence of intestinal obstruction
- Suspected esophageal rupture, unless water-soluble iodinated contrast medium is used
- Suspected tracheoesophageal fistula, unless barium sulfate is used

2.10.4 nursing care before the procedure:

Explain to the client:

- That a physician or a technician will perform the study
- That the procedure requires about 45 minutes to 1 hour
- That foods and fluids are withheld for at least 8 hours before the procedure and should continue to be restricted until the study has been completed
- That the client will be requested to swallow a flavored barium solution while standing in front
- Normal peristalsis through the esophagus into the stomach with normal size and shape of the esophagus; no inflammation, strictures, ulcerations, polyps, tumors, rupture, foreign bodies, varices, or hiatal hernia of a fluoroscopy x-ray screen and that films will be taken while the barium moves down the esophagus. That no pain is associated with the procedure, although swallowing of the contrast medium can be unpleasant (**Bonita Morrow Cavanaugh,2003**)

2.10.5 Prepare for the procedure:

- Obtain a history to ascertain the date of the last menstrual period and pregnancy status, possible allergy to iodine if an iodinated contrast medium is to be used, assessment of gastrointestinal system for signs and symptoms, treatment and medication regimen, and associated diagnostic tests and procedures.
- Ensure that dietary and fluid restrictions have been followed.
- Ensure that all jewelry and clothing are removed from the waist up and provide the client with a gown without metal closures.
- Assess baseline vital signs to compare with later readings or to determine any deviations that can warrant postponement of the study. (**Bonita Morrow Cavanaugh,2003**)

2.10.6 The procedure:

The client is helped onto the x-ray table in a supine position or into a standing position in front of the x-ray screen. An initial plain film is taken. The client stands in front of a fluoroscopic screen and is requested to swallow a barium solution with or without a straw. If the client has problems with chewing or swallowing, small food items coated with barium can be offered. A water-soluble iodinated contrast medium can be used if a rupture of the esophagus is suspected. Barium sulfate, which does not react with the surrounding mucosa, is used if tracheoesophageal fistula is suspected.

The passage of the contrast material through the esophagus is evaluated using fluoroscopic and cineradiologic techniques, and spot films are taken at different angles. The upright position facilitates the diagnosis of strictures or obstructions of the esophagus.

The client is then strapped to the table and the table rotated or tilted into the head-down position, or the client is placed in the prone, supine, and lateral positions for additional films.

The client may be requested to drink additional barium as these films are taken. Delayed films can also be taken to evaluate esophageal abnormalities caused by failure of the barium to completely pass through the esophagus into the stomach. (en.wikipedia.org/wiki/radiology)

2.10.7 Nursing care after the procedure :

- Resume food and fluids if no additional films are to be taken.
- Monitor vital signs and compare with baselines for changes that indicate complications.
- Administer, or advise client to take, a mild laxative and increase fluid intake to aid in the elimination of the barium.
- Inform the client that feces will be whitish or light in color for 2 to 3 days and to notify the physician if the normal color does not return or if the client is unable to eliminate the barium.

Reaction to iodinated contrast medium: Note and report tachycardia, hyperpnea, palpitations, or hypertension. Administer ordered antihistamine or steroid. Initiate IV line and resuscitation procedure, if needed (**Sue C. DeLaune ,Patricia K. Ladner, 2014**)

3.1 Radiologic Angiography Studies :

Angiograms are serial radiographs (x-rays) of blood vessels that are used to evaluate the patency, size, and shape of the veins (venograms); arteries (arteriograms) of organs and tissues; or lymph vessels and nodes (lymphograms). They are films taken in rapid sequence after the injection of an iodinated contrast medium into the vessel or vascular system to be examined.

The contrast medium can be hand injected into a peripheral vessel via a needle or into a major vessel via a needle and catheter, or it can be power injected via a catheter placed directly into a heart chamber and vessels (cardiac catheterization with angiography) to visualize the chambers, great vessels, and coronary arteries.

Successful visualization of any organ or vessel depends on the position of the client and catheter, size and type of the catheter or needle lumen, and the amount and rate of the injection of the contrast medium into the vessel.(**Tracey Hopkins, 2005**)

Various types and shapes of catheters are available for angiography, depending on the tip and length of needle required for the selected vessel to be catheterized .Catheters vary in diameter and length and are made of polyethylene, nylon, polyurethane, and Teflon to accommodate ease of handling, insertion, and injection rates .Injection rates vary with blood flow of the vessel to be injected with the contrast medium and range from 2 to 3 mL per second to a high of 20 to 30 mL per second and a duration range of 2 seconds to 10 or 15 seconds)

The low-osmolality agents cause less pain and fewer adverse reactions and allergic responses than do the conventional ionic agents. Fatality rates have also been reduced with these agents. In rare instances, carbon dioxide can replace the iodinated contrast medium in clients with poor renal function or potentially life-threatening reactions to the other media. Because severe allergic reactions to iodinated contrast media can result in laryngospasms, anaphylactic shock, and cardiac arrest, emergency equipment should be available so that treatment and resuscitative measures can be instituted immediately.

Arterial access for arteriography is achieved by insertion of a catheter through puncture or cutdown into a femoral, axillary, or brachial artery and advancement into the specific artery or vascular system to be examined. Peripheral arteriography can also be achieved by a direct injection of the medium into the target artery, as in the femoral artery.

Venous access for venography is achieved by a direct injection of the contrast medium via venipuncture or cutdown to expose the vein to visualize and evaluate the blood flow of an area. It can also be achieved by injection of the dye into a catheter that has been threaded into the venous system of an

organ, as in arteriography, to visualize and evaluate the venous supply to an area. Both peripheral and central veins are studied with venography.

Angiographic procedures are considered invasive, and a signed informed consent is required. Client preparation is similar to that for a minor surgical procedure, with local anesthesia usually administered for an adult and general anesthesia given to a child or an adult who is unable to cooperate. Cardiopulmonary resuscitation equipment should be available during all angiographic studies. The procedures are performed in a special angiography laboratory or treatment room by a physician with special education and expertise in such procedures. All angiographic procedures are performed under strict sterile conditions and use standard precaution procedures. **(Bonita Morrow. Cavanaugh, 2003)**

3.1.1 Cardiac angiography:

Cardiac and thoracic angiography involves the examination of the heart, great vessels, and coronary arteries. A cardiac catheterization is performed with a catheter inserted into a vein or artery and guided through the vascular system into the left or right side of the heart. The femoral or the brachial artery is the insertion site usually used for left cardiac catheterization and the femoral or the antecubital vein is used for right cardiac catheterization. Films that allow for visualization of the heart structures and activity by cineangiography during and after injection of the dye are taken at a variety of angles as the table is tilted. The client can watch the procedure on a screen, if desired.

A variety of disorders can be diagnosed, depending on which side of the heart is catheterized and studied. Pulmonary artery abnormalities are identified with right heart examination; coronary artery and thoracic aorta abnormalities are identified with left heart examination. The procedure can be performed for therapeutic reasons as well as diagnostic purposes. Special attention is needed and given to provide support and allay the anxiety associated with procedures involving the heart.

Many additional studies of heart structure and function can also be performed during the procedure.

Cardiac catheterization identified a left main coronary artery dissection with occlusion of the left anterior descending artery. The patient underwent urgent four-vessel coronary artery bypass surgery with insertion of an intraaortic balloon pump through the right femoral artery and a left ventricular assist device (LVAD), in order to wean her from cardiopulmonary bypass. Continuous heparin infusion was begun to prevent formation of clots within the LVAD tubing and hypo kinetic left ventricle (Mitchell G. etal, 2007)

3.1.2 interfering factors :

- Inability of client to cooperate in the procedure when local anesthesia is used
- Catheter occlusion caused by stagnant blood
- Atherosclerotic lesions of the vessel to be cannulated, preventing passage of the catheter
- Selection of improper catheter and tip or use of incorrect technique

3.1.3 indications for cardiac angiography :

- Chest pain, especially in clients with cholesterol levels above normal range
- Coronary artery disease, especially in clients with a family history of heart disease
- Identification of abnormalities after questionable results from resting or exercise electrocardiographic (ECG) studies
- Evaluation of angina with frequent and severe episodes of chest pain
- Detection of abnormal coronary circulation and degree of occlusion of the arteries that indicate atherosclerotic disease
- Detection of the extent of heart damage in heart disease
- Identification of myocardial infarction site and performance of infusion procedure of streptokinase or other thrombolytic agent into the occluded vessel
- Evaluation of cardiac status in preparation for cardiac bypass surgery or angioplasty when a

- decreased coronary perfusion is demonstrated
- Evaluation of cardiac function and vessel patency after surgery or angioplasty
- Persistent symptoms (e.g., chest pain) after cardiac revascularization
- Location and determination of the extent of aortic aneurysm and the presence of atherosclerosis of the arch of the great vessel
- Diagnosis of aortic abnormalities by left heart examination such as tumor, diverticula, aortitis, and trauma that create tears or other disruption of the vessel
- Evaluation of progress or decline in condition to enable adjustment of existing medical regimen.

3.1.4 Contraindications;

- Pregnancy, unless the benefits of performing the procedure greatly outweigh the risks to the fetus
- Allergy to radiopaque contrast medium, unless prophylactic medications are administered before the procedure
- Severe cardiomegaly
- Poor or severely impaired renal function
- Poor surgical risk or refusal to undergo surgery if recommended after the procedure (Patricia Gonce Morton, and Dorrie K. Fontaine,2013)

3.1.5 nursing care before the procedure :

Explain to the client:

- That a physician will explain and perform the procedure
- That the time required to complete the procedure varies with the type of examination performed for diagnostic or therapeutic purposes but that it can be 1 to 3 hours
- That foods and fluids are withheld for 4 to 8 hours before the procedure
- That some medications can be withheld for 8 hours before the procedure, depending on the client and the reason for medications taken; that

anticoagulants will be withheld or dosage reduced to prevent excessive bleeding; and that aspirin products are withheld for at least a week before the procedure.

- That an analgesic, sedative, or antianxiety agent can be administered by injection before the procedure to promote relaxation and alleviate discomfort, depending on physician orders.
- That the client is requested to lie still throughout the procedure That an IV line is initiated before the procedure to provide access for the administration of fluids and medications when needed
- That the catheter insertion site will be anesthetized by local injection
- That the client may experience some pressure as the catheter is introduced into the vessel and a feeling of warmth and possible palpitations when the dye is injected, but that this lasts only about 30 seconds
- That cough, nausea, and headache may be experienced during the procedure or that chest pain may develop during the injection or during exercises that are part of the examination and that medications are given if these side effects occur That continuous monitoring by ECG and vital signs is performed during and after the procedure That bed rest is required for about 8 to 12 hours after the procedure to monitor the insertion site and vital signs and to observe the client for signs of complications, although complications are rare)

3.1.7 prepare for the procedure:

- Ensure that dietary, fluid, and medication restrictions have been followed before the procedure.
- Obtain a history of allergies or sensitivities to the anesthetics or contrast medium; existing heart, lung, or renal condition; and date of last menstrual period in women of childbearing age to determine the possibility of pregnancy.

- Ensure that hematologic status and blood clotting ability have been assessed to include complete blood count, platelet count, PT, PTT, clotting time, and bleeding time as well as routine urinalysis and electrolytes. Note and record results of ECG and chest x-ray.
- Remove all metallic objects, but allow client to wear dentures, hearing aids, or both. Obtain and record baseline vital signs, using peripheral pulses on the appropriate extremity.
- Mark these sites on the skin to ensure that the same location is used to monitor and compare readings to assess circulatory status after the procedure.
- Shave and cleanse insertion site if needed.

Administer premedication SC or intramuscularly as ordered. (Premedication can include an analgesic such as meperidine [Demerol], a sedative such as diazepam [Valium], or an antihistamine such as diphenhydramine to prevent an allergic reaction in those with a history of sensitivity to iodine.) (**Bonita Morrow .Cavanaugh 2003**)

3.1.8 The procedure:

The client is placed on a tilting type x-ray table in a supine position with straps in place to prevent falling and to keep the client very still during the procedure. Cardiopulmonary resuscitation equipment, defibrillator, pacemaker, and cardiac medications should be on hand during and after the procedure. The operating room is notified of the procedure in the event that emergency cardiac surgery is necessary.

The leads from the ECG machine are attached to the chest for continuous monitoring. An IV access line is initiated to keep the vein open for the administration of fluids and drugs when needed. The site is cleansed and draped to prepare a sterile field. A local anesthetic is injected at the site, and a small incision is made.

The room is darkened, and a needle with a guide wire is inserted. When the needle and guide wire are placed in the desired site in the heart and coronary vessels or great vessels, the needle only is removed, and the catheter is threaded onto the wire and advanced into the vessel under the guidance of fluoroscopy. The guide wire is then removed, and the catheter is flushed with heparinized saline solution to remove any stagnant blood, a procedure that is repeated every 3 minutes throughout the study. The catheter is advanced through the selected vein to the inferior vena cava and then to the right atrium and ventricle if the right side is being catheterized or through the selected artery to the aorta and into the coronary arteries if the left side is being catheterized. The coronary arteries can be catheterized singly to evaluate patency. After correct placement and flushing of the catheter, the iodinated contrast medium is injected and controlled at a rate determined by the studies to be performed. A rapid series of x-rays are taken during and after the injection.

www.cancer.org/sslink/imagingradiologica

During the procedure, the client can be requested to deep-breathe or cough to counteract nausea and to ease catheter placement into the pulmonary artery as well as to move the diaphragm in a downward position to allow for clearer visualization of the heart.¹⁴ Filming takes place with the table tilted in different positions, and the client is turned from side to side to obtain views of the heart at a variety of angles. Vital signs and heart activity are monitored continuously to observe for dysrhythmias that can occur during the procedure. The procedure is terminated if severe chest pain, cardiac dysrhythmias, or symptoms of cerebral accident are noted. When the procedure is completed, protamine sulfate is administered to counteract the effect of the heparin and to prevent excessive bleeding. The catheter is removed, the incision site sutured, and a bandage applied and taped in place. (Bonita Morrow . Cavanaugh 2003)

3.1.8 Nursing care after the procedure:

- Remove the client from the x-ray table and place him or her at rest for 8 to 12 hours after the procedure to prevent bleeding from the puncture site. Time at rest should depend on pressure at the insertion site (venous or arterial) and whether more than one site was used.
- Elevate the head of the bed to 45 degrees and extend the extremity used for the insertion site. Immobilize the extremity with a sandbag, 8 hours for a leg and 3 hours for an arm.
- Inspect the insertion site for bleeding or hematoma formation, and change the pressure dressing as needed.
- Apply ice to the site to relieve discomfort and edema by promoting vasoconstriction of the vessels at the site.
- A mild analgesic can be administered for site pain.
- Assess skin color, sensation, and temperature of the extremity to determine circulation status.
- Take peripheral pulses of the extremity used and compare with pre procedure pulses and pulses of the other extremity.
- Perform this assessment every 15 minutes for the first hour, then every 30 minutes for the next 2 hours, and then every hour for the next 8 hours or more if needed.
- Take vital signs and apical pulse at the same frequency.
- Encourage movement in bed from side to side to exercise uninvolved body parts.
- To prevent dehydration and promote excretion of the dye, encourage fluids, first via the IV line and then orally, when client is able. Sutures, if used, are removed in a week.
- Reaction to anesthetic agent or contrast medium:
- Note and report tachycardia, dyspnea, hyperpnea, or delayed feeling of itching (urticaria, rash).

- Administer antihistamines and steroids. Initiate oxygen and resuscitation procedure if needed.
- Dysrhythmias, cardiac tamponade: Note and report irregular pulse, postprocedural ECG changes, or signs and symptoms of cardiac tamponade such as anxiety, tachypnea, muffled heart sounds, distended neck veins, or narrowing pulse pressures.
- Administer ordered cardiac medications. Monitor vital signs and cardiac activity via ECG.
- Thrombophlebitis: Note and report pain/redness, swelling at the site, or changes in the peripheral pulses. Monitor site for changes. Apply ordered warm compresses.
- Infection at the insertion site: Note and report pain, swelling, or drainage. Administer ordered analgesic and antibiotic therapy. Apply heat treatments. **(Bonita Morrow .Cavanaugh,2003)**
- Bleeding, hematoma: Note and report excessive bleeding from the insertion site or presence of a hematoma. Apply pressure for 15 minutes after the procedure. Apply ice bag and pressure dressing

3.2 Ultrasound Studies :

Ultrasound is a noninvasive instrumentation procedure that uses sound waves in the frequency range of 20,000 to 10 billion cycles per second, a sound range beyond that audible to the human ear, to obtain diagnostic information or to perform therapeutic protocols.

Techniques to display the echo wave image include A and B modes. The A mode presents the information in a graphic form as in an echocardiogram or echoencephalogram.

The B mode presents the information in varying intensities of brightness by the use of dots that coalesce to form an anatomic outline as in fetal, pancreatic, kidney, spleen, and bladder sonograms. Realtime scanning uses a multiple transducer to display rapid sequencing of motion that resembles a movie.

It allows imaging of a moving fetus, the motion of the heart, and the movement involved with larger blood vessels.³ The presence of fluid provides an excellent medium for transmission of the waves to organs or other areas to be visualized.

The diagnostic value of ultrasound studies is in the ability of the sound waves of varying intensities to outline the shape and position of organs and tissues of the body and the ability to detect pathology such as masses, edema, stones, and displacement of adjacent tissues. These abilities are possible because abnormal tissue is of a different density and elasticity than is the normal tissue in the same area. Because ultrasonography can be performed quickly, it is frequently used when time is important. It is limited as a useful diagnostic method in studies of bones or of air- or gas-filled organs such as the lungs or intestines. .the ultrasound procedure Depending on pathological findings revealed with ultrasound, more invasive studies such as radiology or radionuclide scanning can follow to further clarify and diagnose abnormalities.

Ultrasound studies are performed on inpatients and outpatients in the hospital, physician's office, or medical imaging agency in a specially equipped room. A skilled technician usually performs the procedure to ensure satisfactory studies, and a radiologist with special education and expertise interprets the findings. No anesthesia is needed because no pain is experienced during ultrasonography. Signed informed consent forms are not required for these studies unless accompanied by fine-needle biopsy. It is very safe to use and does not appear to cause any adverse effects. It is also relatively inexpensive and quick to perform. Ultrasound scanners can be taken to critically ill patients in intensive care units, avoiding the danger caused while moving the patient to the radiology department. The real time moving image obtained can be used to guide drainage and biopsy procedures. Doppler capabilities on modern scanners allow the blood flow in arteries and veins to be assessed.

Advantages of abdominal ultrasonography are that it requires no ionizing radiation, there are no noticeable side effects, and it is relatively inexpensive.

One disadvantage is that it cannot be used to examine structures that lie behind bony tissue, because bone prevents sound waves from passing to deeper structures. Gas and fluid in the abdomen or air in the lungs also prevent transmission of ultrasound. (http://en.wikipedia.org/wiki/Medical_imaging)

3.2.1 Ultrasound risks

There is no evidence at this time to indicate that ultrasound is harmful if given at the appropriate low intensity doses. It is a noninvasive procedure unrelated to x-ray studies; thus, there is no exposure to radiation or use of contrast-mediated materials. The greatest known risks to tissues associated with these studies are the production of heat that occurs when the level of waves exceeds the maximum frequency recommended for diagnostic procedures. These higher frequencies are reserved for the therapeutic destruction of bacteria or tumor cells and require an ultrasound instrument designed to deliver this level for a calculated period. Ultrasound diagnostic equipment is designed to deliver a safe level of energy that prevents this known risk.

The use of Doppler monitoring of a fetus has been an acceptable practice, but the use of the ultrasound technique for arterial studies produces some heat in tissues and is considered to be damaging to a fetus.

3.2.2 Ultrasound procedures :

Ultrasound procedures are named for the organ or region of the body to be examined. Among them are the liver, pancreas, heart, brain, and almost all other organs; vessels such as the aorta; or an entire region consisting of several organs, such as the abdomen or pelvis. Depending on the region or organ to be studied, the transducer or probe is placed in various positions, angles, and rotations. Client position also varies with the site to be studied and includes supine, prone, sitting, semierect, left lateral, and right or left oblique. Scanning is performed in two planes before any images are taken, and all films are made in at least two scanning planes. The planes available for scanning include the sagittal, transverse.

Ultrasound is used to evaluate the brain, thyroid gland, heart, vascular structure, abdominal aorta, spleen, liver, gallbladder, pancreas, and pelvis. An ultrasound is commonly done during pregnancy to evaluate the size of the fetus and placenta; a full bladder is needed to ensure visualization. Instruct the mother to drink 6 to 8 glasses of water and to avoid urination before testing. (Sue C. DeLaune Patricia K. Ladner,2002)

3.2.3 Abdominal ultrasonography :

Ultrasonography is a noninvasive diagnostic technique in which high-frequency sound waves are passed into internal body structures and the ultrasonic echoes are recorded on an oscilloscope as they strike tissues of different densities. During abdominal ultrasonography, an image of the abdominal organs and structures is produced on the oscilloscope.

This procedure is generally used to indicate the size and configuration of abdominal structures. It is particularly useful in the detection of cholelithiasis, cholecystitis, and appendicitis. Most recently this technique has proven useful in diagnosing acute colonic diverticulitis.

. Endoscopic ultrasonography (EUS) is a specialized enteroscopic procedure that aids in the diagnosis of GI disorders by providing direct imaging of a target area. It helps in staging of a tumor, including size, spread, and whether the tumor is operable. It is useful in evaluating transmural changes in the bowel wall that occur in ulcerative colitis. Intestinal gas, bone, and thick layers of adipose tissue (all of which hamper conventional ultrasonography) are not problems when this technique is used.

3.2.3.1 Nursing Interventions :

- The patient fasts for 8 to 12 hours before the test to decrease the amount of gas in the bowel. If gallbladder studies are being performed,
- the patient should eat a fat-free meal the evening before the test. If barium studies are to be performed, the nurse should make sure they are scheduled after this test; otherwise, the barium will interfere with the transmission of the sound waves. (brunner and sudders , 2010)

3.2.4 Abdominal/aortic ultrasonography:

Abdominal/aortic ultrasonography a study performed to assist in the diagnosis of aortic aneurysm and to determine its size by display of constriction or dilation of the vessel. Because it is a safe procedure, it can be repeated as often as every 6 months to monitor changes in the size of this great vessel. Ultrasound is performed alone or in combination with Doppler techniques to identify the vessel lumen and associated clot formation within an abdominal aortic aneurysm. The area scanned includes the complete abdomen from the umbilicus to the xiphoid process and includes adjacent organs.

3.2.4.1 Interfering factors :

- Inability of client to remain still during the procedure
- Incorrect placement and movement of the transducer over the desired sites
Gas, feces, or barium in the bowel that attenuates the sound waves
- Increased bowel motility that affects sound waves
- Obesity that increases space between the organs and the transducer, affecting the transmission of waves to and from the abdomen Scar tissue from previous surgery that prevents transmission of waves through the skin to the abdominal organs .

3..2.4.2 Indications for abdominal/aortic ultrasonography:

- Detecting and measuring an aortic aneurysm within the abdomen for deviations from the normal diameters at various sections of the vessel .
- Monitoring aortic aneurysm expansion periodically to prevent rupture revealed by measurements of 7 cm or more in diameter or rapid increases in size
- Determining changes in small aortic aneurysms before and after abdominal surgical procedures
- Differentiating between the vessel lumen and a clot within an aortic aneurysm with the use of Doppler technique in combination with ultrasonography

- Diagnosing pathology of intra-abdominal organs such as the liver, spleen, pancreas, gallbladder, and kidneys, singly or in groups
- Determining patency and function of vessels and ducts such as the portal vein, splenic vein, renal arteries and veins, superior and inferior mesenteric veins, and biliary and pancreatic ducts
- Determining ascites fluid status and the best site for a diagnostic paracentesis
- Diagnosing abdominal pathology during pregnancy, because the fetus is not at risk during ultrasound (Sandra M. Nettina, 2001)

3.2.4.3 Nursing care before the procedure ;

- Client teaching and physical preparation are the same as those for any ultrasound procedure
- Obtain a history that includes a suspected or existing abdominal aortic aneurysm and the results of the last measurement of aneurysm diameter to use as a comparison.
- Inform the client that food is restricted for 12hours before the study, but encourage fluids to provide a full bladder that pushes the bowel out of the pelvis for scanning.
- Administer an enema to remove feces and barium, and administer simethicone (Mylicon) to reduce gas from the bowel if ordered.

3.2.4.4 The procedure:

The client is placed on the examination table in a supine position. The abdomen is exposed and draped for privacy. The client can be requested to lie on either side or assume a sitting position during the scanning. A conductive gel is applied to the abdominal scanning sites. The transducer is rotated and manipulated over the abdomen, avoiding any scar tissue, from the xiphoid process to the aortic bifurcation and to the left and right of the midline.

This process provides scanning of the aorta and other sites of the abdominal organs and vessels. Impulses are transmitted from the device to a screen for visual display and are photographed for future viewing and comparisons. When the studies are completed, the gel is removed from the abdomen. Care and assessment after the procedure are the same as those for any ultrasound procedure.

Inform the client that food intake can be resumed. Normal structure of the abdominal organs; normal contour and normal diameter of the abdominal aorta of 1.5 to 2.5 cm at various sections of the vessel. Sudden changes in vital signs and continuous abdominal or back pain can indicate an expanding aneurysm, and sudden onset of severe pain, hypotension, tachycardia, and diaphoresis indicate aneurysm rupture. Both require immediate reporting and Nursing interventions. (Bonita Morrow, 2003)

3.2.5 Bladder ultrasonography:

Bladder ultrasonography is a study performed to visualize the size and contour of the bladder by providing an outline of the organ while it is full of urine. Abnormal contour changes or distortion of bladder position is an indication of pathology of the pelvic organs or bladder wall. The procedure can be performed with ultrasonography of the kidneys, ureters, bladder, urethra, and gonads to diagnose renal/urologic disorders.

3.2.5.1 Interfering factors:

- Inability of client to remain still during the procedure
- Incorrect placement of the transducer over the test site
- Barium or gas in the bowel or small amount of residual urine in the bladder.

3.2.5.2 Indications for bladder ultrasonography:

- Assessing residual urine after voiding to diagnose urinary tract obstruction
- Detecting tumor of the bladder wall or pelvis revealed by distortion in position or change in contour of the bladder.
- Determining bladder malignancy resulting from an extension of a primary tumor of the ovary or other pelvic organs

3.2.5.3 Nursing care before the procedure:

- Client teaching and physical preparation are the same as those for any ultrasound procedure .
- Obtain a history that includes any disease or dysfunction of the urinary bladder, therapy received, and results of tests and procedures associated with the urinary bladder.
- Encourage fluid intake to ensure a full bladder Normal size, position, and contour of the urinary bladder; no masses or urinary residual to enhance imaging of the organs or have client void immediately before the procedure if residual volume is to be measured.

3.2.5.4The procedure:

The client is placed on the examination table in a supine position. The lower abdomen is exposed and draped for privacy. The bladder is palpated to ensure that it is full of urine and a conductive gel is applied to the area. A transducer is manipulated over the bladder and pelvic sites, and sound waves are projected onto the screen and photo-graphed for immediate and future viewing. If the client is to be examined for residual urine volume, the bladder is emptied, the procedure repeated, and the volume calculated. When the study is completed, the gel is removed from the abdominal sites.

3.2.5.5Nursing care after the procedure:

Care and assessment after the study are the same as those for any ultrasound procedure .(Bonita Morrow . Cavanaugh,,2003)

3.3. Echocardiography :

echocardiography is used to identify the primary abnormality and determine the ejection fraction. cardiac catheterization may be needed to exclude cad.

Echocardiography is an ultrasound study performed to assist in the diagnosis of cardiovascular disorders. It allows visualization of the internal cardiac structures for size, shape, position, and movement.

All four valves, both ventricles, and the left atrium, as well as the velocity of the blood flow, can be examined during the movement of the transducer over the chest. Electrocardiography (ECG) and phonocardiography can be conducted simultaneously to correlate the findings with the cardiac cycle. which produces a linear tracing of timed motions of the heart and its structures, and the two-dimensional method, which produces a cross-section of the structures of the heart and their relationship to one another as well as changes in the coronary vasculature. Another method, used to detect blood-flow pattern and velocity in the heart valves and great vessels, is color-flow Doppler imaging. The differences in blue and red hues are photographed to identify the blood-flow directions and velocities. A combination of these methods is used to obtain a complete study of the heart and its structures. An important consideration in performing echocardiography is using it in combination with other noninvasive tests in the diagnosis of heart disorders rather than resorting to invasive procedures such as cardiac catheterization and angiography in higher risk clients (Patricia Gonce Morton ,and Dorrie K. Fontaine,2013)

3.3.1 Interfering factors :

- Inability of client to remain still during the procedure Obesity, chest thickness, deformity, or other abnormality or trauma that can increase the space between the heart and the transducer, which can affect transmission of waves to and from the chest
- Chronic obstructive pulmonary disease (COPD) or use of mechanical ventilation that can increase the air between the heart and chest wall (hyperinflation), which attenuates the ultrasound waves Dysrhythmias that can affect the test results
- Incorrect placement and movement of the transducer over the proper sites or lack of skill in performing the procedure

3.3.2 Indications for echocardiography:

- Detecting and determining the severity of mitral valve abnormalities such as torn chordae, stenosis, prolapse, regurgitation, or failure of valve closure revealed by restriction of valve leaflet motion or displacement of a valve leaflet
- Detecting and determining the severity of aortic valve abnormalities such as stenosis or failure of valve closure revealed by regurgitation and valve thickening
- Diagnosing subaortic stenosis
- reduction in aortic valve flow based on the obstruction
- Diagnosing pulmonary hypertension and pulmonary valve stenosis revealed by echo changes at the pulmonary valve site
- Diagnosing cardiomyopathy associated with cardiac chamber wall defects revealed by large- or small-sized chamber internal dimensions and wall thickness measurements that are less or more than should be expected.
- Diagnosing cardiac tumors revealed by echoes in the vicinity of the mitral or tricuspid valves
- Determining the presence of pericardial effusion revealed by an absence of echoes between the left ventricular epicardium and pericardium an caused by fluid between these membranes
- Determining the extent of coronary artery disease revealed by the absence of or abnormal ventricular wall movements resulting from infarction or ischemia
- Detecting ventricular or atrial mural thrombi and evaluating wall motion after myocardial infarction In infants and children,
- diagnosing congenital heart defects such as ventricular or atrial septal defect, pulmonary or aortic stenosis, coarctation of the aorta, patent ductus arteriosus, transposition of the great vessels, hypoplastic ventricles, tetralogy of Fallot, truncus arteriosus, and other cardiac malpositions and anomalies

- Determining congestive heart failure revealed by an enlarged chamber size
- Detecting changes in valve motion after rheumatic fever exacerbations in children
- Detecting direction of blood flow and changes in velocity of the flow (Doppler echocardiography) by imaging of the great vessels and right-to-left shunting of blood in children with congenital heart defects.
- Determining the dimensions for the root of the aorta to detect the true and false lumens in aortic dissection
- Determining the cause of unexplained chest pain, ECG changes, and abnormal chest x-ray (enlarged cardiac silhouette)
- Evaluating or monitoring prosthetic valve function.

3.3.3 Nursing care before the procedure:

Explain to the client:

- That the procedure takes about 30 to 45 minutes
- That there are no food or fluid restrictions before the study
- That the client will be placed in appropriate positions and requested to remain still, turn, or sit up during the procedure
- That a gel substance will be applied to the skin of the area to be viewed and a device placed and rotated over the area
- That a picture is produced on a screen that the client can see, if desired

That no pain or risk of complications is associated with the procedure (**Patricia Gonce Morton ,and Dorrie K. Fontaine,2013**)

3.3.4 Prepare for the procedure:

- Obtain a history of previous or existing cardiac conditions, therapeutic regimen, and results of related laboratory tests and procedures.
- Assist client to remove clothing from the waist up and provide a hospital gown if client is an outpatient; otherwise, ensure that a hospital gown is worn with the opening in front.

- Obtain vital signs for later comparison readings.
- Offer the client an opportunity to void before the procedure for comfort.

3.3.5 The procedure :

The client is placed on the examination table in a supine position. A portion of the chest is exposed and ECG leads are attached to the chest for simultaneous recording of heart activity during ultrasound.

The client should receive explanations for the use of ECG. conductive gel is applied to the chest slightly to the left of the sternum. The transducer is placed on the surface of the chest along the left sterna border, subxiphoid area, suprasternal notch, or supraclavicular areas to obtain views and tracings of portions of the heart. The area is scanned by systematic movement of the probe in a perpendicular position to direct the ultrasound waves to each part of the heart. To obtain different views or information about heart function, the client is placed on the left side and in sitting positions and requested to breathe slowly, hold the breath during the procedure. If the client is requested to inhale a vasodilator such as amyl nitrite (Vaporole) to identify changes in function of the heart, assessment is made for side effects such as dizziness or tachycardia. When the study is completed, the leads and gel are removed from the chest.

3.3.6 Nursing care after the procedure:

- Tell the client when the physician will have and reveal the results, usually 1 to 2 days after the study. (Cavanaugh, Bonita Morrow, 2003)

3.3.7 Nursing interventions :

Before traditional echocardiography, the nurse informs the patient about the test, explaining that it is painless. Echocardiographic monitoring is performed while a transducer that emits the sound waves is moved about the chest. Gel applied to the skin helps transmit the sound waves. Periodically, the patient will have to turn onto the left side or hold a breath. The test takes about 30 to 45 minutes. If the patient is to undergo an exercise or pharmacologic stress test with echocardiography, information on stress testing is also reviewed. (Cavanaugh, Bonita Morrow, 2003)

4.1magnetic resonance imaging:

Magnetic resonance imaging (MRI) is a noninvasive, painless technique that is used to examine both the physiologic and anatomic properties of the heart. MRI uses a powerful magnetic field and computer-generated pictures to image the heart and great vessels. It is valuable in diagnosing diseases of the aorta, heart muscle, and pericardium, as well as congenital heart lesions. The application of this technique to the evaluation of coronary artery anatomy, cardiac blood flow, and myocardial viability in conjunction with pharmacologic stress testing is being investigated. An MRI is an imaging test that uses powerful magnets and radio waves to produce detailed, computer-generated pictures of organs and tissue inside the body, including the brain and spinal column. An MRI can be used to: Find a tumor

Determine, in some situations, if a tumor is benign (noncancerous) or malignant (cancerous) Learn more about the stage of cancer (the size and location of the tumor) Help doctors plan cancer treatments, such as surgery or radiation therapy Monitor a tumor's response to treatment (**American society of clinical oncology, 2014**).

4.2 Nursing interventions:

Because of the strong magnetic field used during MRI, diagnostic centers where these procedures are performed carefully screen patients for contraindications.

Standardized questionnaires are commonly used to determine whether the patient has a pacemaker, metal plates, prosthetic joints, or other metallic implants that can become dislodged if exposed to MRI. During an MRI, the patient is positioned supine on a table that is placed into an enclosed imager or tube that contains the magnetic field.

People who are claustrophobic may need to receive a mild sedative before undergoing an MRI. As the MRI is performed, there is an intermittent clanking or thumping sound from the magnetic coils that can be annoying to the patient, so patients are offered headsets to listen to music. The scanner is equipped with a microphone so that the patient can communicate with the staff art.(**Brunner and suddarths, 2010**)

3.1 Study design:

Descriptive, cross-sectional hospital-based study, done in Elmek Nimer university hospital to assess nurses knowledge and practice regarding medical imaging studies. From the period from July to November 2014.

3.2 Study area:

The study is carried out at Shendi town which is 176km north to Khartoum and 110 km south to Elddamer, the capital of River Nile State; Shendi town is lies on the eastern bank of the River Nile with a total area of about 14596 Km².

The total population of Shendi 'locality ' is estimated at about 197589 of whom 116713 live in rural areas and 80876 in urban centers, most of them are farmers. Shendi University was established in the early 1990s and stands as a landmark institution in Higher Education.

There are three big hospital; Elmek Nimer university hospital, Shendi hospital teaching and military hospital.

3.3 Setting:

Elmek Nemer hospital established in 2002, located in Shendi city it including many department such as medicine, pediatric, surgery, obstetric, renal center and cardiac center.

3.4 Study population:

Include all nurses' work in Elmek Nemer during the three shifts Both sexes.

3.5 Sampling:

The study population was selected by simple random sample.

3.6 Sample size:

The study include 80 nurses whom were participated during the study.

3.5 Materials

3.5.1 Data collection tools:

Data was be collected by closed ended questionnaire to fulfill the purpose of the study. It compose of (23) questions. It included the fallowing parts.

Part 1 Concerned with Gathering Data in Relation to:

Characteristics: (sociodemographic data):

Including (Age, sex, qualification, years of experience,).

Part two (medical imaging as general):

Including patient consent, techniques, nursing care, uses, The knowledge of nurses was assessed regarding uses and nursing care, The route and hazard, Interfering factors. Fast of ultrasound and 18. Purpose of Fluoroscopy, Purpose and . Interfering factor, nursing care and indications.

3.5.2Data collection technique:

The data was collected by closed ended questionnaire and fullful by participant themselves .

3.5.3Data analysis:

Data were coded and transferred into special designed formats for data entry then data were analyzed and computed using the statistical package for social sciences (SPSS version 16.0). And presented in forms of table and figure.

3.5.4 Ethical consideration:-

An explanation of the aim of the study was given to every nurse before their involvement in the study. written was obtained; each study subject was individually interviewed.

They were assured that all the gathered data will be used for research purpose only. Participants', confidentiality, privacy, safety and protection were secured.

Table (1): Distribution of nurses according to their socio-demographical data(age, gender, level of education and experience)7

Items		Frequency	Percent	Total
Age :	20- 25years	38	47.5 %	80 100 %
	26- 30year	35	43.8 %	
	more than 31 years	7	8.8 %	
Gender:	male	14	17.5 %	
	female	66	82.5 %	
Level of education:	diploma	4	5 %	
	bachelor	67	83.8 %	
	master	9	11.2 %	
Experience years:	Less than 2 year	29	36.2 %	
	3- 4years	35	43.8 %	
	more than 5 years	16	20 %	

Table (1) reflects that the majority of nurses (82 %) were female; their age nearly half (47.5%) was between 20-25years, have a bachelor certificate (83%).and more than two fifth (43%) have experience years between (3-4)

Table (2): Distribution of nurses according to their knowledge regard medical imaging definition

Medical imaging is	Frequency	Percent
Diagnostic	35	43.8%
Therapeutic	9	11.2%
Both	36	45%
Total	80	100

regard medical imaging definition table showed that less than half of nurses define medical imaging as diagnostic and therapeutic procedure (45 %).by the other hand more than two third (43.8) mentioned as diagnostic procedure.

Table (3): Distribution of nurses according to their knowledge regard medical imaging techniques:

Techniques	Frequency	Percent
Invasive	29	36.2%
Noninvasive	24	30%
Both	27	33.8%
Total	80	100

The above table showed that more than one third (36.2) mentioned that medical imaging techniques as invasive.

Table (4): Distribution of nurses according to their knowledge regard general nursing care of patient for medical imaging

knowledge	Frequency	Percent
Good knowledge	33	41.2%
Satisfy knowledge	16	20%
Poor knowledge	31	38.8%
Total	80	100

Table(4)showed that more than two fifth (41.2) have a good knowledge about nursing care of patient for medical imaging

Table (5): Distribution of nurses according to their knowledge regard consent request

procedure	Frequency	Percent
Invasive	60	75%
Non-invasive	20	25%
Total	80	100

The above table showed that more than two third (75%) of nurses mentioned that consent requested in invasive procedure.

Table (6): Distribution of nurses according to their knowledge regard types of radiologic angiography:

Types	Frequency	Percent
Cardiac catheterization	32	40%
Arteriogram	14	17.5%
Both	34	42.5%
Total	80	100

The above table showed that more than two fifth (42.5%) have a good knowledge regard types of radiologic angiography

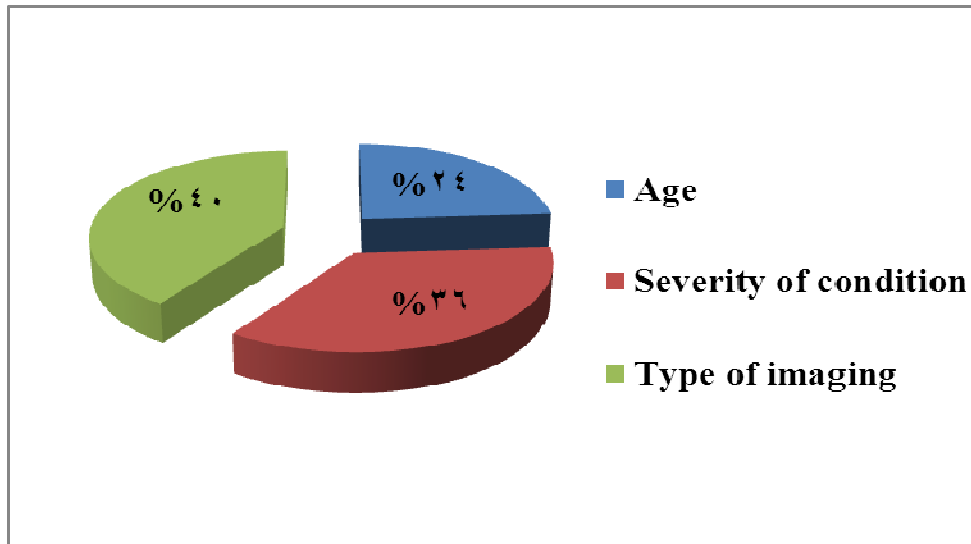


Figure (1): Distribution of nurses according to their knowledge regard nursing care for patient undergoing medical imaging depend on:

explain more than tow third(73.7%) of nurses mention nursing care for patient undergoing medical imaging depend on.

Table (7): Distribution of nurses according to their knowledge regards X .Ray using

X Ray using	Frequency	Percent
Bones	39	48.8%
Organs	3	3.8%
Both	38	47.5%
Total	80	100

Table (7) reflects that (48.8 %), (47.5) mentioned uses of x, ray for bones, bones and organs, respectively

Table (8): Distribution of nurses according to their knowledge regards pre - nursing care of x ray film and C.T scan

knowledge	Frequency	Percent
Good knowledge	23	28.8%
Satisfy knowledge	27	33.8%
Poor knowledge	30	37.5%
Total	80	100

The above table showed that more than one third (37.5%) have a poor knowledge about pre - nursing care of x ray film and C.T scan

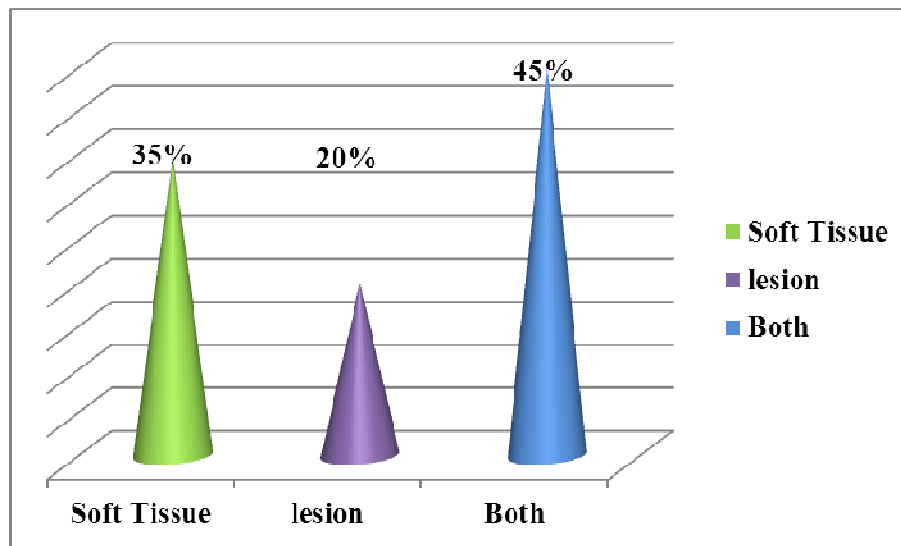


Figure (2): Distribution of nurses according to their knowledge regards Ct scans usage

Figure (2) explain that more than two fifth (45 %) of nurses mentioned C.Tscan used for soft tissue and lesion

Table (9): Distribution of nurses according to their knowledge regards the route and the hazard of Contrast media for x-ray :

Route	Frequency	Percent	Total
orally	11	13.8%	80 100 %
I.V	37	46.2%	
Both	32	40%	
Good knowledge	17	21.2%	80 100 %
Satisfy knowledge	27	33.8%	
Poor knowledge	36	45%	

Table (9) concern that less than half (46.2%) mentioned the rout of contrast media is I.V, by the other hand (45%) have a poor knowledge about hazards.

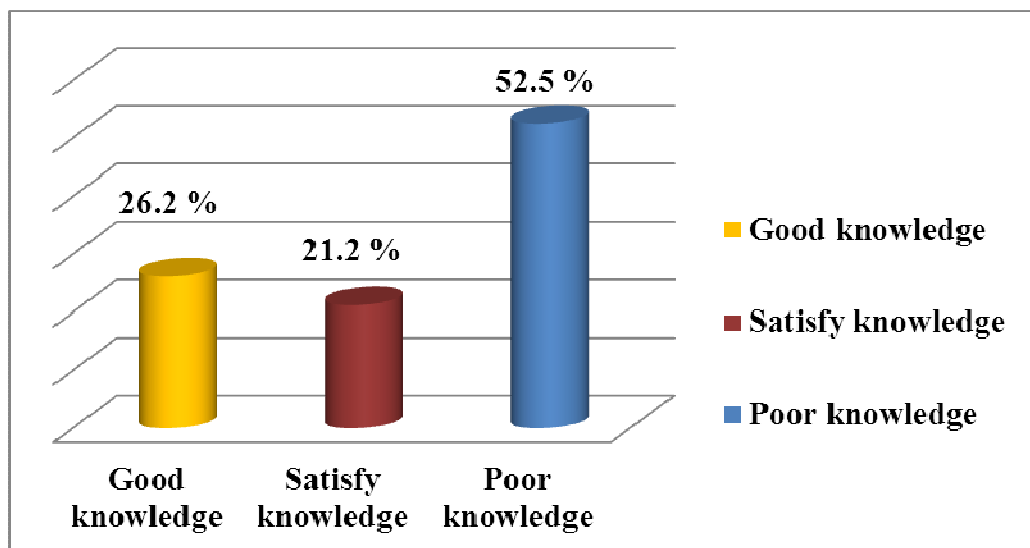


Figure (3): Distribution of nurses according to their knowledge regards interfering factors for abdomen ultrasound

Figure (2) showed that more than half (52.5 %) have a poor knowledge about interfering factor s for abdomen ultrasound

Table(10): Distribution of nurses according to their knowledge regards the patient fasting for ultra sound test

Fasting	Frequency	Percent
4 hour	43	53.8%
6 hours	37	46.2%
Total	80	100

Table (9) reflect that more than half (53.8) of nurses mentioned that the hours of fasting is 4 hr, but less than half (46.2) mentioned as 6 hr.

Table (11): Distribution of nurses according to their knowledge regards the advantage of ultrasound

knowledge	Frequency	Percent
Good knowledge	22	27.5%
Satisfy knowledge	20	25%
Poor knowledge	38	47.5%
Total	80	100

The above table explain less than half (47.5 %) have a poor knowledge about advantage of ultrasound

Table (12): Distribution of nurses according to their knowledge regards the purpose of Fluoroscopy

knowledge	Frequency	Percent
Good knowledge	13	16.2%
Satisfy knowledge	14	17.5%
Poor knowledge	53	66.2%
Total	80	100

The above table explain that two third (66.2 %) have a poor knowledge about purpose of Fluoroscopy

Table (13): Distribution of nurses according to their knowledge regards the interfering factor with barium swallow and advice after barium swallowing procedure

Knowledge	Frequency	Percent	Total
The interfering factor			
Good knowledge	19	23.8%	80 100%
Satisfy knowledge	23	28.8%	
Poor knowledge	38	47.5%	
Advice after barium			
Good knowledge	12	15%	80 100%
Satisfy knowledge	34	42.5%	
Poor knowledge	34	42.5%	

Table(12) concern less than half (47.5 %) have a poor knowledge about interfering factor with barium swallow, while more than two fifth (42.5%) have same percentage (satisfy and poor knowledge

Table(14): Distribution of nurses according to their knowledge regards indications for echocardiography and nursing care for patient in echo

Knowledge	Frequency	Percent	Total
Indications			
Good knowledge	38	47.5%	80 100 %
Satisfy knowledge	14	17.5%	
Poor knowledge	28	35%	
Nursing care			
Good knowledge	42	52.5%	80 100 %
Satisfy knowledge	18	22.5%	
Poor knowledge	20	25%	

The above table explains that less than half (47.5 %), more than half (52.5) of nurses has a good knowledge about indications for echocardiography, and nursing care for patient in echo, respectively.

Table (15): Distribution of nurses according to their knowledge regards interfering factor for MRI

knowledge	Frequency	Percent
Good knowledge	34	42.5%
Satisfy knowledge	13	16.2%
Poor knowledge	33	41.3%
Total	80	100

Table (15) explain more than two fifth (42.5 %) have a good knowledge about interfering factor for MRI

Table. (16) The relation between the years of experience and general nursing care for patient for medical imaging (n=80).

		General nursing care for patient for medical imaging			Total	P-Value
		Goode knowledge	satisfy knowledge	poor knowledge		
experience	less.than2year	10	5	14	29	0.00
	3_4years	14	7	14	35	
	more than5years	9	4	3	16	
Total		33	16	31	80	

*** Significant at P. value ≤ 0.05**

**** Highly significant at p. value ≤ 0.001**

Table. (17) the relation between the years of experience and the hazard of radiation with contrast media (n=80).

		the hazard of radiation with contrast media			Total	P-Value
		good knowledge	satisfy knowledge	poor knowledge		
experience	less.than2year	4	10	15	29	0.00
	3_4years	9	9	17	35	
	more than5years	4	8	4	16	
Total		17	27	36	80	

*** Significant at P. value ≤ 0.05**

**** Highly significant at p. value ≤ 0.001**

Table. (18) the relation between the level of education and nursing care for patient undergoing medical imaging depend on (n=80).

		Nursing care for patient undergoing medical imaging depend on			Total	P-Value
		Good knowledge	Satisfy knowledge	Poor knowledge		
Level of education	Diploma	1	1	2	4	0.03
	Bacalorea	15	16	36	67	
	Master	6	2	1	9	
Total		22	19	39	80	

* Significant at P. value ≤ 0.05

** Highly significant at p. value ≤ 0.001

Discussion

This study was done in Elmek Nimer university hospital to assess nurse knowledge, and role regarding medical imaging studies in period extended from July to October.

The study reflects that the majority of nurses (82 %) were female; their age nearly half (47.5%) was between 20-25years, have a bachelor certificate (83%).and more than two fifth (43%) have experience years between (3-4). The study show that less than half of nurses define medical imaging as diagnostic and therapeutic procedure (45%).On the other hand more than two third (43.8%) mentioned as diagnostic procedure. The study showed that more than one third (36.2) mentioned that medical imaging techniques as invasive. This result show moderate knowledge about medical imaging studies that reflect the nurse be not updating need more training .

. The study showed that more than two fifth (42.5%) have a good knowledge regard types of radiologic angiography That reveal the nurse is moderate knowledge about types of radiologic angiography.

The study explain more than tow third (73.7%) of nurses mention nursing care for patient undergoing medical imaging depend on type of medical imaging This mean most of nurses in hospital good educated (bacclorria). The result reflects that (48.8 %), (47.5) mentioned uses of x, ray for bones, bones and organs, respectively.

The result showed that more than one third (37.5%) have a poor knowledge about pre - nursing care of x ray film and C.T scan

This study reveal poor knowledge of nurses because have no practice pre x ray or ct.scan in their hospital that indicate need for practice updating and course .

The study is explain that more than two fifth (45 %) of nurses mentioned C.T scan used for soft tissue and lesion .That clarify of good knowledge for nurses about it. The result explain that less than half (46.2%) mentioned the rout of contrast media is I.V, by the other hand (45%) have a poor knowledge about hazards

This result show poor knowledge about rout and hazard of contrast media because this procedure perform in cardiac catheter and and nurse in other department not wear about it .

The present study showed that more than half (52.5 %) have a poor knowledge about interfering factor s for abdomen ultrasound otherwise, less than half (47.5 %) have a poor knowledge about advantage of ultrasound ,and more than half (53.8) of nurses mentioned that the hours of fasting is 4 hr, but less than half (46.2) mentioned as 6 hr. This bad. the hour before ultrasound 6huors and lead to miss diagnose and wrong treatment so that nurses need to be enough experiences .

The result concern that two third (66.2 %) have a poor knowledge about purpose of Fluoroscopy ,because the most of nurse have no endoscopy training .

The collective data clarify that less than half (47.5 %) have a poor knowledge about interfering factor with barium swallow, while more than two fifth (42.5%) have same percentage (satisfy and poor knowledge . Because barium swallow study perform irregular procedure pattern. that less than half (47.5 %), more than half (52.5) of nurses has a good knowledge about indications for echocardiography, and nursing care for patient in echo, respectively . although MRI are not available in hospital in spite of good knowledge about echo. The study explain more than two fifth (42.5 %) have a good knowledge about interfering factor for MRI.

Conclusion

Based on the finding of present study it was concluded that :

Most of study population have poor knowledge about medical imaging and type and their using. Most of study population have poor knowledge about information of contrast media and ultrasound and fluoroscopy and barium swallow .

The study is explain that more than two fifth of nurses mentioned C.T scan used for soft tissue and lesion .That clarify of good knowledge for nurses about it. The result explain that less than half (46.2%) mentioned the rout of contrast media is I.V, by the other hand (45%) have a poor knowledge about hazards

Most of study population has good knowledge about information of echocardiography and MRI and their nursing care.

Recommendations

On the light of the results, the following recommendation can be made:

1- Establish continuous local training program regarding medical imaging and education program for nurses.

References

1. **American Society for Gastrointestinal Endoscopy,2010.** The role of endoscopy in the management of patients with known and suspected colonic obstruction and pseudo-obstruction. www.giejournal.org Volume 71, No. 4 : 2010.
2. **American society of clinical oncology, 2014.**
<http://www.cancer.net/navigating-cancer-care/diagnosincancer/tests-and-procedures>, Magnetic Resonance Imaging (MRI).
3. **American Society of Radiologic Technologists.** The Practice Standards for Medical Imaging and Radiation Therapy, 2014.
4. **Bonita Morrow and Cavanaugh,.** Nurses manual of laboratory and diagnostic test. ,.fourth edition 2003;page 363-482.
5. **Brunner &Suddarth's 2010.** text book of medical surgical nursing , Suzanne C. O'Connell Smeltzer, Brenda G. Bare, edition 10: pages 949,985,990,991,992,994,1452,1453.
6. **Caroline bunker rosdahl, mary t. Kowalski, 2o12.**textbook of basic nursing ,10th edition, , ,page 434,436,544,588.
7. **Clinical imaging radiotherapy and oncology.** Consent to Imaging and Radiotherapy Treatment Examinations. First edition .August 2007
8. Cynthia C. Chernecky, Barbara J. Berger,2007.Laboratory Tests and Diagnostic Procedures, 5th edition.
9. **Patricia Gonce Morton, Dorrie K. Fontaine2013.** Essentials of Critical Care Nursing aHolistic Approach, , ninth edition,2013 page 189,199.201.231.479
- 10.linda s. williams, paula d. hopper,2003.understanding medical-surgical nursing, second edition, ,page 819,900.
- 11.**Mitchell G. Scott, Ann M. Gronowski, Charles S. Eby,2007,**Tietz'sAppliedLaboratoryMedicineSecond Edition, page 456,610.
- 12.**National radiation laboratory,** code of safe practice for the use of x-rays in medical diagnosis national ,january 1994 revised june 2010.
- 13.**Patricia Gonce Morton, and Dorrie K. Fontaine 2013.** Essentials of Critical Care Nursing A Holistic Approach, , 9th ed. page,199.
- 14.**Penelope Ann Hilton, 2004.**Fundamental nursing skills Edited, First published 2004,page 85,86.
- 15.**Sandra M.Netina, 2001.** Manual of nursing practice 8th edition, Lippincott 2006;page 745_748.

16. **Sue C. DeLaune ,Patricia K. Ladner:** Fundamentals of Nursing: Standards & Practice, Second Edition, 2002 page 665 ,1294 , 2014 from <http://www.cancer.net/navigating-cancer-care/diagnosing-cancer/tests-andprocedures> , Computed Tomography (CT) Scan.

17. **Tracey Hopkins 2005.** GuidLAB Notes guide to lab diagnostic test , Pages, 90, 115, 125, 175

Web sites:

18. http://en.wikipedia.org/wiki/Medical_imaging.

19. en.wikipedia.org/wiki/radiology, on line access 9:36pm 16.9.2014

20. www.cancer.org/sslink/imagingradiologica

University of Shendi
Faculty of graduate studies and scientific research
Questionnaire about assessment of the nurses knowledge and role
regarding medical imaging studies

Part (1):Demographical data

1. Age:

- a. 20-25 years () b. 26-30years () c. More than 31years ()

1. Gender:

- a. Male () b. Female ()

2. Level of education:

- a. Diploma () b. Bachelor () c. Master ()

3. Experience years:

- a. Less than 2 years () b. 3-4 years () c. More than 5 years.

Part (2) RELATED TO MEDICAL IMAGING:

4. Medical imaging is:

- a. Diagnostic () b. therapeutic ()

5. Medical imaging is techniques:

- a. Invasive () b. non invasive ()

6. General nursing care for patient for medical imaging:

- a. take history () b. Vital sing () c. explanation procedure ()
d. physical examination ().

7. Consent is request in radiological procedure:

- a. Invasive () b. non invasive ()

8. Types of radiologic angiography:

- a. Cardiac catheter () c. Arteriogram()

9. Nursing care for patient undergoing medical imaging depend on :-

- a -Age () b - severity of condition ()
c - type of medical imaging ()

10. X Ray is used form:

- a. Bones () c. organ ().

11. Pre procedure nursing care of x ray film and C.T scan include :

- a. Take history ()
- b. Remove jewelry and eyeglasses ()
- c. General examination ()

12. Ct scans are used for:

- a. soft tissue ()
- b. .lesion ()

13. The route of Contrast media for x-ray by:

- a .Orally ()
- b. I.V ()

14. The hazard of radiation with contrast media:

- a. vomiting ()
- b. allergic reaction ()
- c. anaphylactic Shock ()

15. Interfering factor s for abdomen ultrasound:

- a. Feces ()
- b. Ascites ()
- c. Obesity ()

16. The patient fasts before the ultra sound test for at least:

- a. 4 hours ()
- b. 6 hours ()

17. The advantage of ultrasound:

- a. Non expensive ()
- b. there is no ionizing radiation ()
- c. Speed ()

18. Purpose of Fluoroscopy:

- a. Digestive system ()
- b. Movement of diaphragm ()
- c . Heart as angiography ()

19. Interfering factor with barium swallow:

- a. Inability of client to swallow ()
- b. Foods and fluids ingested within 8 hours ()
- c. Metal objects ()

20. Advise after barium swallowing procedure:

- a. Take more fluid ()
- b. T take laxative ()
- c . Check vitals sig ()

21. Nursing care for patient in echo :

- a. The client will place in appropriate position ()
- b. Apply gel on the skin of area ()
- c. Assess client to remove clothing ()

22. Indications for echocardiography:

- a. Mitral valve abnormalities. ()
- b. aortic valve abnormalities ()
- c. sub aortic stenosis ()

23. Interfering factor for MRI IS:

- a. Metal plates () b. prosthetic joints ()
- c. other metallic implants ()