



GLOBAL JOURNAL OF MEDICAL RESEARCH: I  
SURGERIES AND CARDIOVASCULAR SYSTEM  
Volume 18 Issue 3 Version 1.0 Year 2018  
Type: Double Blind Peer Reviewed International Research Journal  
Publisher: Global Journals  
Online ISSN: 2249-4618 & Print ISSN: 0975-5888

# Chemical Management of Anal Fissure without Headache and Hypotension

By Elssayed Osman Elssayed, Omer Alsharif, Mohammed Omer Abass  
& Abdelrahman Babekir Mhammed

*Shendi University*

**Abstract-** Anal fissure is a linear or oval-shaped tear in the anal canal starting just below the dentate line extending to the anal verge.

**Objective:** To evaluate the efficacy and complications of GTN with Vaseline base in the period between January 2014 to June 2018 in Almak Nimir University Hospital Shendi University (Sudan).

**Methodology:** This study was a prospective, hospital-based, small-scale study conducted in the period between April 2014 to April 2018 in Almak Nimir University Hospital Shendi University (Sudan). 155 patients with acute & chronic anal fissure treated with GTN with Vaseline base (22 patients excluded due to incomplete follow up).

**Result:** One hundred and fifty-five patients were enrolled: twenty-two patients excluded due incomplete follow up. The maximum number of cases of anal fissure belonged to the 21 to 30 age group. Success rate up to 94 % with and negligible site effect (1.5%).

**Keywords:** glyceryl trinitrate (gtn), chronic anal fissure (caf), internal anal sphincter (ias), resting anal pressure (rap).

**GJMR-I Classification:** FOR Code: NLMC Code: WE 700



CHEMICAL MANAGEMENT OF ANAL FISSURE WITHOUT HEADACHE AND HYPOTENSION

*Strictly as per the compliance and regulations of:*



© 2018. Elssayed Osman Elssayed, Omer Alsharif, Mohammed Omer Abass & Abdelrahman Babekir Mhammed. This is a research/review paper, distributed under the terms of the Creative Commons Attribution-Noncommercial 3.0 Unported License (<http://creativecommons.org/licenses/by-nc/3.0/>), permitting all non-commercial use, distribution, and reproduction in any medium, provided the original work is properly cited.

# Chemical Management of Anal Fissure without Headache and Hypotension in Almak Nimir University Hospital

Elssayed Osman Elssayed <sup>α</sup>, Omer Alsharif <sup>σ</sup>, Mohammed Omer Abass <sup>ρ</sup>  
& Abdelrahman Babekir Mhammed <sup>ω</sup>

**Abstract-** Anal fissure is a linear or oval-shaped tear in the anal canal starting just below the dentate line extending to the anal verge.

**Objective:** To evaluate the efficacy and complications of GTN with Vaseline base in the period between January 2014 to June 2018 in Almak Nimir University Hospital Shendi University (Sudan).

**Methodology:** This study was a prospective, hospital-based, small-scale study conducted in the period between April 2014 to April 2018 in Almak Nimir University Hospital Shendi University (Sudan). 155 patients with acute & chronic anal fissure treated with GTN with Vaseline base (22 patients excluded due to incomplete follow up).

**Result:** One hundred and fifty-five patients were enrolled: twenty-two patients excluded due incomplete follow up. The maximum number of cases of anal fissure belonged to the 21 to 30 age group. Success rate up to 94 % with and negligible site effect (1.5%).

**Conclusion:** GTN 2% in Vaseline base was effective in the treatment of anal fissure with an efficacy up to 94% and negligible site effect (1.5%).

**Keywords:** glyceryl trinitrate (GTN), chronic anal fissure (CAF), internal anal sphincter (IAS), resting anal pressure (RAP).

## I. INTRODUCTION

An Anal fissure is a linear or oval-shaped tear in the anal canal starting just below the dentate line extending to the anal verge. It was first described in 1934 by Lockhart-Mummery. [1, 2]

Chronic fissures may associate with a sentinel pile or anal papilla. The majority of occur in the posterior midline (90%), although anterior midline fissures seen in 10-20% of affected women and 1-10% of affected men (3).

## II. ETIOLOGY

The pathogenesis of chronic anal fissure remains poorly understood. The sphincter spasm seems to cause relative local ischemia that precludes the healing (4) (5).

Many reports have documented that anal hypertonia means elevated maximal resting anal pressures (RAP) higher than 90 mm Hg [6 - 9] and is

related to the internal anal sphincter because resting pressures returned to normal values after internal sphincterotomy [10, 11]. Anal hypertonia of IAS produces ischemia of the posterior commissure of the anus [9, 12, 13]. It was postulated that increased anal pressure precedes the development of anal fissure, and there is evidence that psychological stress produces a sustained tonic rise in anal canal pressure, translating into an increased tone in the IAS [12 - 15].

A morphological description offers a more precise definition. The CAF presents thickened edges with usually visible, internal anal sphincter fibers at the fissure base. It may also be associated with skin tag (the sentinel pile) at the lower end of the fissure and/or a papilla at the upper end of a fissure (hypertrophied anal papilla) [16, 17, 18].

The presenting complaints documented in the study by Khubchandani and Reed were the pain (23.5%), bleeding (76.2%), itching (34.9%) and an anal lump (24.3%) and burning sensation in the anal region (33%) (19).

### a) Medical Therapy

Initial therapy for an anal fissure is medical, and more than 80% of acute anal fissures resolve without further. The goals of treatment are to relieve constipation and to break the cycle of hard bowel movement and associated pain. Softer bowel movements are less painful for the patient to pass.

First-line medical therapy consists of therapy with stool-bulking agents, such as fiber supplementation and stool softeners. Laxatives used as needed to maintain regular bowel movements. Mineral oil may be added to facilitate passage of stool without as much stretching or abrasion of the anal mucosa, but it was not recommended for indefinite use. Sitz baths after bowel movements and as needed provide significant symptomatic relief because they relieve some of the painful internal sphincter muscle spasms.

Recurrence rates are in the range of 30-70% if the high-fiber diet abandoned after the fissure healed. This range can be reduced to 15-20% if patients remain on a high-fiber diet.

Second-line medical therapy consists of an intra-anal application of 0.4% nitroglycerin (NTG): also

**Author α ρ ω:** MBBS, MD, Assistant Professor of General Surgery, Faculty of Medicine, Shendi University.

e-mail: elssayedosman@gmail.com

**Author σ:** BS Pharm (Pharmacist).

called glycerol tri-nitrate) ointment directly to the internal sphincter. [20].

#### b) Pharmacological Sphincter Relaxants

Interest in the pharmacologic manipulation of the IAS was spurred by the recognition that sphincter hypertonia associated with fissure persistence, and that surgical approaches to decreased tone may lead to permanent dysfunction. The IAS consists of smooth muscle whose tone is caused partially by intrinsic myogenic properties and partly to extrinsic neural influences [21, 22, 23] Nitric oxide is the principal noradrenergic, noncholinergic neurotransmitter in the IAS [24, 25] and its release results in IAS relaxation. IAS contraction is mediated by increased cytosolic calcium levels [21, 26] Calcium-channel blockers conversely reduce IAS tone.  $\alpha$ 1-Adrenergic stimulation leads to IAS contraction, whereas  $\beta$ -adrenergic and muscarinic cholinergic agonists lead to IAS relaxation (21).

Topical Glyceryl trinitrate cream a nitric oxide donor compound has been shown to cause relaxation of anal sphincter (27).

Conventional myorelaxant creams such as topical nitroglycerin, nifedipine, and calcium channel blockers have all proven to be efficacious in treating anal fissures, albeit less so than lateral internal sphincterotomy [28, 29]. Unfortunately, different studies have reported associated moderate to severe side effects, ultimately resulting in non compliance and treatment failure [30, 31]. Nitroglycerin causes headaches and hypotension in over 70% of patients [32, 33], and diltiazem causes perianal itching [34].

The drawbacks to topical GTN are intolerance due to side effects and overall poor patient compliance. Systemic absorption of the compound can result in vasodilation and severe headaches. Headaches are a problematic side effect of topical GTN, and up to 20% of patients had to discontinue therapy. (35).

### III. PATIENTS AND METHODS

This study was a prospective, hospital-based, small-scale study conducted in the period between

January 2014 to June 2018 in Almak Nimir University Hospital Shendi University (Sudan). 155 patients with acute & chronic anal fissure treated with GTN with Vaseline base (22 patients excluded due to incomplete follow up), the anal fissure was defined as ulceration in the posterior or anterior an oderm or post de factory pain. Patients with other conditions (perianal fistulas or abscesses) excluded.

### IV. METHODS

A total of 133 patients, 43 patients (32.3%) with chronic anal fissure and 90 patients (67.7) with acute anal fissure aged between 15 and 70 years were included in this study / and were subjected to non-operative management with 2% GTN in Vaseline base twice daily for six weeks.

Patients re-evaluated at 2 and, six weeks, during follow-up, history and perianal examination were performed, and patients' records reviewed, parameters, relief of symptoms, pain relief, bleeding per rectum and healing of fissure were evaluated. Complications of treatment, headache, dizziness and significant drop in blood pressure recorded.

The response to treatment registered as complete (symptomatic remission and complete fissure cicatrization), partial (symptomatic improvement but the persistence of the fissure), refractory (without symptomatic improvement or fissure cicatrization) and relapse (recurrence of symptoms and appearance after complete response).

The primary endpoint of the study was complete healing and symptomatic improvement after GTN treatment. Statistical analysis was performed using SPSS.

### V. RESULTS

Most of the patients belonged to the age group 21-30 (39.1%), and the age of 71-80 is less affected, with a slight male preponderance (51.1% 49.9%).

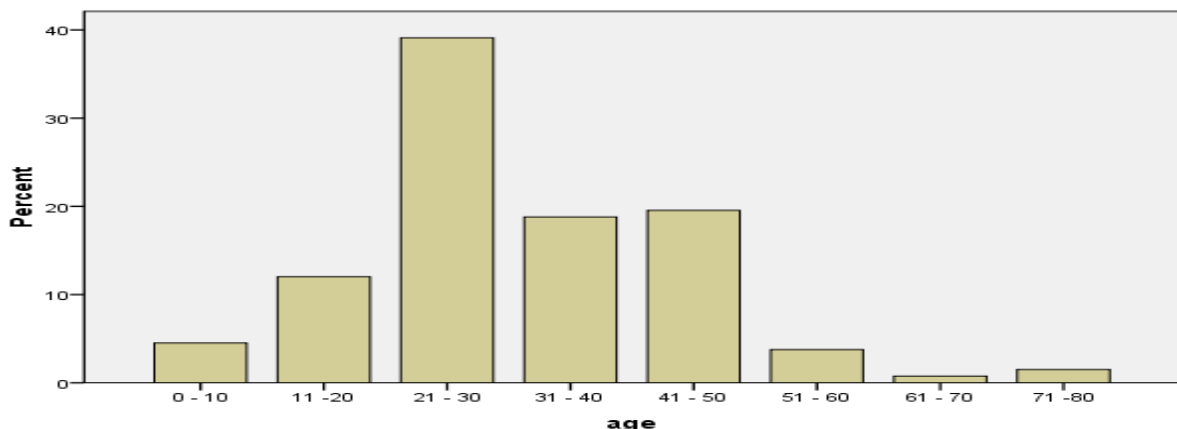


Fig. 1: Distribution of Patients According to Age.

Table 1: Distribution of Patients According to Sex.

Gender	No. of Patients %
Male	68 (51.1%)
Female	65 (48.9%)

100 patients (75.2%) had pain during defecation as their presenting symptom, bleeding per rectum in 8 patients (6 %), while both pain and bleeding in 25 patients (18.8%) and of whom 72.2% of patients had a history of constipation

Table 2: Distribution of Symptoms

Symptoms	No of Patients N=134	Percentage (%)
Pain During Defecation	100	75.2 %
Pain & Bleeding	25	18.8 %
Bleeding	8	6 %
Constipation	96	72.2 %

The clinical signs in the study were a posterior anal fissure in 112 patients (84.2%), an anterior anal fissure in 9 patients (6.8%), while six patients (4.5%) in both and 12 patients (9%) had a tender digital rectal examination.

Table 3: Distribution of Clinical Signs

Clinical Signs	No. of Patients
Posterior Anal Fissure	107 Patients (80.5%)
Anterior Anal Fissure	8 Patients (6%)
Both	6 Patients (4.5)
Tender Digital Rectal Examination	12 Patients (9%)

By two weeks 128 patients (96.2%) achieved symptom relief, by the six week the number decrease to 125 patients who respond to the management (94%)

Table 4: Patients who respond to GTN by Two Weeks & 6 Weeks

Relief of Symptoms		
2 Weeks	6 Weeks	
Respond	128 (96.2%)	125 (94%)
Not Respond	5 (3.8%)	8 (6%)

131 patients (98.5%) not express a headache or symptom of hypotension after treatment with GTN.

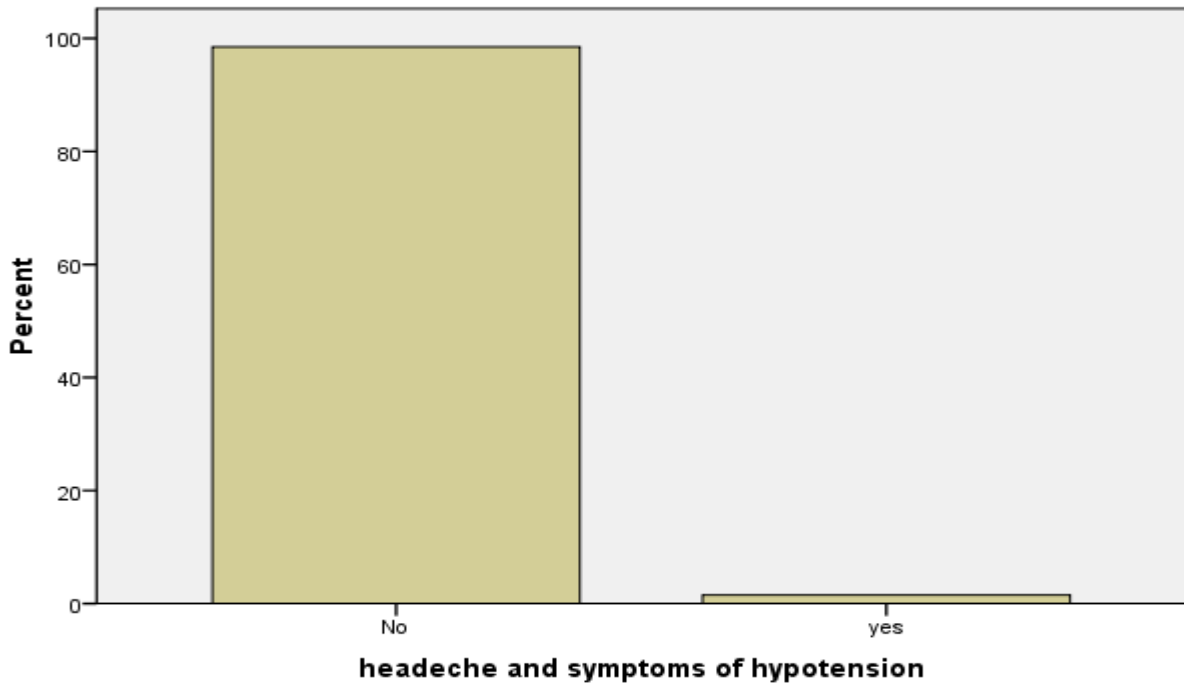


Fig. 2: Patients who Express a Headache

## VI. DISCUSSION

An anal Fissure is a disease of young adults as most of the published studies agreed on, Hananel and Gordon, they state that Fissure most commonly seen in middle-aged and younger patients (1) Jensen SL studied 90 patients with acute anal fissure, and reported a mean age of 46(36) Raj V. K. and Kadam M. M. has observed that 36.67% of acute fissure and 43.33% of chronic fissure cases occurs in the age group between

21-30 years old (39). We had similar results in the present study, with the maximum number of cases of anal fissure belonged to 21 to 30 age group. There were six cases of an acute anal fissure in less than 10-year age group. The lax anal sphincter is the reason for the rarity of the disease among the patients above the age of 60 years (figure 1).

Concerning gender there was no variation in distribution, Jensen SL reported an equal incidence of male and female patients (36) Giridhar C. M. etal. have

observed that 56.6% male patients and 43.3% female patients had an anal fissure (37). According to Kari S. S. et al, while studying 100 patients with an anal fissure, 56 % of patients were males (38) In the present study there is a slight male predominance with 51.1% of patients being males. (table 1).

Raj V. K. and Kadam M., found that Intense pain during and after defecation with or without bleeding per rectum are the symptoms with which a patient of an acute anal fissure usually presents to (93.33%) (39). Hananel N. and Gordon in a review of 876 patients, pain and bleeding were the main complain (90.8% & 71.4%) respectively (1).

In the present study, the most common presentation of an anal fissure was pain during defecation 100 patients (75.2%), followed by both pain & bleeding per rectum 25 (18.8%) cases. Constipation was present in 96(72.2%) cases (Table 2).

Hananel N. and Gordon in their study found, 75 % of the anal fissure was anterior, while posterior anal fissure in 25% (1). In our study posterior location, the figure was higher 107 (80.5%) cases, while anteriorly was found in 8 (6%) cases, both posterior and anterior was in 6 patients (4.5%). Painful on examination without fissure in 12 (9%) cases (Table 3).

The majority of acute anal fissures managed medically. In fact, almost half will heal with conservative therapy alone using warm baths and increased fiber intake. (5, 40) [20]. In his study, Shubetal, found that 44% of fissure healed conservatively within four weeks. (41).

All the patients enrolled in the present study 133 patients, 128 patients (96.2%) achieved symptom relief within two weeks by using GTN (in Vaseline base) stool softeners, sitz bath, and lignocaine ointment, while five patients (3.8%) not responded. Patients in whom there was no relief of symptoms after two weeks of conservative management, were subjected to surgical management. By the six weeks the number decrease to 125 patients who respond to the treatment (94%) achieved symptom relief (no pain or bleeding, ulcer healing) (table 4).

Chemical sphincterotomy with nitrates may generate headache in 20%-30% (35)(42) of cases or even a higher rate (43). Other study, nitroglycerin causes both headache and hypotension in over 70% of patients [32,33]. Systemic absorption of the compound was the cause of the problem due to vasodilation and up to 20% of patients had to discontinue therapy (35), which was absent in this study no patient stops the treatment due to side effect, either a headache or symptoms of hypotension and increase the success rate up to 94 % (table 5).

Nelson R & Perry WB and his group in two different studies they conclude that the dose of GTN (0.2% or 0.4%) was not found to influence the efficacy but did increase the incidence of side effects, headache, which occurred in about a quarter of patients

[42,44]. In our study a headache is not significant, was only noticed in two patients (1.5%).

A systematic review of the literature was undertaken two databases (Pub Med, MEDLINE) were searched, this is the first study in the literature used GTN 2 % in Vaseline base, they use GTN ointment with different concentration (0.2% & 0.4%) [42,44] in spite of that we have two patients (1.5%) who experience headache, Vaseline base was found to be the major contributing factor in preventing absorption of GTN systemically.1

## VII. CONCLUSION

GTN 2% in Vaseline base was very good in the treatment of anal fissure with an efficacy up to 94% and negligible site effect (1.5%). So we can conclude that a headache is not a headache in patients using GTN.

## REFERENCES RÉFÉRENCES REFERENCIAS

1. Hananel N., Gordon P. H. Re-examination of clinical manifestations and response to therapy of fissure-in-ano. *Dis Colon Rectum*. 1997; 40 (2): 229-233.
2. Lockhart-Mummery J. P. London: Baillere: 1934. *Diseases of the Rectum and Colon and Their Surgical Treatment*.
3. Notaras M. J. The treatment of anal fissure by lateral subcutaneous internal sphincterotomy: a technique and results. *Br J Surg*. 1971; 58 (2): 96-100.
4. Nothmann, B. J. and Schuster, M. M. Internal anal sphincter derangement with anal fissure, *Gastroenterology*. 1974; 67: 216-220.
5. Schouten, W. R., Briel, J. W., and Auwerda, J. J. Relationship between anal pressure and anodermal blood flow. The vascular pathogenesis of anal fissures. *Dis Colon Rectum*. 1994; 37: 664-669.
6. McCallion K., Gardiner K. R. progress in the understanding treatment of chronic anal fissure. *Postgrad Med J* 2001; 77: 753-758. doi:10.1136/pmj.77.914.753.
7. Utzing M. J., Kroesen A. J., Buhr H. J. Concepts in pathogenesis and treatment of chronic anal fissure: a review of the literature. *Am J Gastroenterol* 2003; 98: 968-974.
8. Farouk R., Duthie G. S., Mac Gregor A. B., Bartolo D. C. Sustained internal sphincter hypertonia in patients with chronic anal fissure. *Dis Colon Rectum* 1994; 37: 424-429. doi:10.1007/BF02076185.
9. Schouten W. R., Briel J. W., Auwerda J. J., De Graaf E. J. Ischemic nature of anal fissure. *Br J Surg* 1996; 83: 63-65. doi:10.1002/bjs.1800830120.
10. Cerdan F. J., Ruiz de Leon A., Azpiroz F. Anal sphincteric pressure in fissure in ano before and after lateral internal sphincterotomy. *Dis Colon Rectum* 1982; 25: 198-201. doi:10.1007/BF02553100.



11. Chowcat N. L., Arango J. G., Boulos P. B. Internal sphincterotomy for chronic anal fissure: Long term effects on anal pressure. *Br Surg* 1986; 73: 915-916. doi:10.1002/bjs.1800731123.
12. Gibbon C. P., Read N. W. Anal hypertonia in fissures: Cause or effect? *Br J Surg* 1986; 73: 443-445. doi:10.1002/bjs.1800730609.
13. Ayantunde A. A., Samuel A. D. Current concept in anal fissures. *World J Surg* 2006; 30: 2246-2260. doi:10.1007/s00268-005-0664-y.
14. Ancock B. D. The internal sphincter and anal fissure. *Br J Surg* 1977; 64: 92-95. doi:10.1002/bjs.1800640204.
15. Boulos P. B., Araujo J. G. Adequate internal sphincterotomy for chronic anal fissure: subcutaneous or open technique? *Br J Surg* 1984; 71: 360-362. doi:10.1002/bjs.1800710517.
16. Dykes S. L., Madoff R. D. Benign Anorectal: Anal Fissure. In: Wolff B. G., Fleshman J. W., Beck D. E., Pemberton J. H., Wexner S. D., et al., editors. *The ASCRS textbook of colon and rectal surgery*. New York: Springer Science and Business Media LLC; 2007. PP. 178-191.
17. Wollina U. Pharmacological sphincterotomy for chronic anal fissures by botulinum toxin a. *J Cutan Aesthet Surg*. 2008; 1: 58-63.
18. Brisinda G., Cadeddu F., Brandara F., Brisinda D., Maria G. Treating chronic anal fissure with botulinum neurotoxin. *Nat Clin Pract Gastroenterol Hepatol*. 2004; 1: 82-89.
19. Khubchandani I. T., Reed J. F. Sequelae of internal sphincterotomy for chronic fissure in ano. *Br J Surg*. 1989; 76: 431-4.
20. Schiano di Visconte M., Munegato G. Glyceryl trinitrate ointment (0.25%) and anal cryothermal dilators in the treatment of chronic anal fissures. *J Gastrointest Surg*. 2009 Jul. 13 (7): 1283-91.
21. Bhardwaj, R., Vaizey, C. J., Boulos, P. B., and Hoyle, C. H. Neuromyogenic properties of the internal anal sphincter: therapeutic rationale for anal fissures. *Gut*. 2000; 46: 861-868.
22. Frenckner, B. and Ihre, T. Influence of autonomic nerves on the internal anal sphincter in man. *Gut*. 1976; 17: 306-312.
23. Frenckner, B. Function of the anal sphincters in spinal man. *Gut*. 1975; 16: 638-644.
24. O'Kelly, T., Brading, A., and Mortensen, N. Nerve mediated relaxation of the human internal anal sphincter: the role of nitric oxide. *Gut*. 1993; 34: 689-693.
25. Rattan, S. and Chakder, S. Role of nitric oxide as a mediator of internal anal sphincter relaxation. *Am J Physiol*. 1992; 262: G107-G112.
26. Cook, T. A., Humphreys, M. M., and Mortensen, N. J. Oral nifedipine reduces resting anal pressure and heals chronic anal fissure. *Br J Surg*. 1999; 86: 1269-1273.
27. Suvarna R., Hanumanthappa M. B., Panchami Rai D. G. Topical diltiazem versus topical glyceryl trinitrate (GTN) in the treatment of chronic anal fissure: prospective study. *Int J Biol Med Res* 2012; 3 (2): 1747-5.
28. Karamanlis E., Michalopoulos A., Papadopoulos V., et al. Prospective clinical trial comparing sphincterotomy, nitroglycerin ointment and xylocaine / lactulose combination for the treatment of anal fissure. *Tech Coloproctol* 2010; 14 (suppl 1): S21-3.
29. Ahmed H. M. Comparative study of oral and topical nifedipine in the treatment of chronic anal fissure. *Sudanese Journal of Public Health*. 2010; 5 (4): 203-8.
30. Altomare D. F., Rinaldi M., Milito G., et al. Glyceryl trinitrate for chronic anal fissure-healing or headache? Results of a multicenter, randomized, placebo-controlled, double-blind trial. *Dis Colon Rectum* 2000; 43: 174-9. [PubMed].
31. Watson S. J., Kamm M. A., Nicholls R. J., et al. Topical glyceryl trinitrate in the treatment of chronic anal fissure. *Br J Surg* 1996; 83: 771-5.
32. Berry S. M., Barish C. F., Bhandari R., et al. Nitroglycerin 0.4% ointment V/s placebo in the treatment of pain resulting from chronic anal fissure: a randomized, double-blind, placebo-controlled study. *BMC Gastroenterol* 2013; 13: 106.
33. Aslam M. I., Pervaiz A., Rigueiredo R. Internal sphincterotomy versus topical nitroglycerin ointment for chronic anal fissure. *Asian J Surg* 2014; 37: 15-9.
34. Samim M., Twigt B., Stoker L., et al. Topical diltiazem cream versus botulinum toxin A for the treatment of chronic anal fissure. A double-blind randomized clinical trial. *Ann Surg* 2012; 255: 18-22.
35. Brisinda G., Maria G., Bentivoglio A. R., Cassetta E., Gui D., Albanese A. A comparison of injections of botulinum toxin and topical nitroglycerin ointment for the treatment of chronic anal fissure. *N Engl J Med*. 1999; 341 (2): 65-69.
36. Jensen S. L. Treatment of first episode of acute anal fissure-a prospective, randomized study of lignocaine ointment versus hydrocortisone ointment versus warm Sitz bath plus bran. *BMJ*. 1986; 292 (6529): 1167-9.
37. Giridhar C. M., Babu P., Rao K. S. A comparative study of lateral sphincterotomy and 2% diltiazem gel local application in the treatment of chronic fissure in ano. *J Clin Diag Res: JCDR*. 2014; 8 (10): NC01.
38. Kuri S. S., Saha A. K., Mandal N., Ganguly S. S. Comparative study of lateral sphincterotomy versus local 2 % Diltiazem ointment for the treatment of chronic anal fissure. *IOSR-JDMS*. 2014; 13 (6): 36-40.

39. Raj V. K, Kadam M. M. A study on different modalities in management of fissure in ano. *Int J Sci Res.* 2014; 3 (10):.942-8.
40. Lund J. N., Scholefield J. H. Aetiology and treatment of anal fissure. *Br J Surg.* 1996; 83 (10): 1335-44.
41. Shub H. A., Salvati E. P., Rubin R. J. Conservative treatment of anal fissure: an unselected, retrospective and continuous study. *Dis Colon and Rectum.* 1978; 21 (8): 582-3.
42. Perry W. B., Dykes S. L., Buie W. D., Rafferty J. F.. Practice parameters for the management of anal fissures (3<sup>rd</sup> revision) *Dis Colon Rectum.* 2010; 53: 1110-1115.
43. Carapeti E. A., Kamm M. A., McDonald P. J., Chadwick S. J., Melville D., Phillips R. K. Randomised controlled trial shows that glyceryl trinitrate heals anal fissures, higher doses are not more effective, and there is a high recurrence rate. *Gut.* 1999; 44: 727-730.
44. Nelson R. Non-surgical therapy for anal fissure. *Cochrane Database Syst Rev.* 2006; 18: CD003431.

